

**A Thesis Submitted for the Degree of PhD at the University of Warwick**

**Permanent WRAP URL:**

<http://wrap.warwick.ac.uk/168755>

**Copyright and reuse:**

This thesis is made available online and is protected by original copyright.

Please scroll down to view the document itself.

Please refer to the repository record for this item for information to help you to cite it.

Our policy information is available from the repository home page.

For more information, please contact the WRAP Team at: [wrap@warwick.ac.uk](mailto:wrap@warwick.ac.uk)

# Targeted Graft Specific Immunosuppression to Improve Outcomes in Reconstructive Transplantation

Dr C Anton Fries

A thesis submitted in fulfilment of the requirement for a PhD by published works,  
Warwick Medical School, University of Warwick

21 August 2021

<b>Table of Contents</b>	<b>Page</b>
Declaration	4
Index of published works for consideration	5
Statement of candidate's contribution to the published work	6
Acknowledgements	8
Abbreviations	9
<b>Prologue</b>	10
<b>Chapter 1 - Introduction to Vascularized Composite Allotransplantation</b>	
1.1 Introduction	12
1.2 Conditions considered suitable for treatment by Vascularized Composite Allotransplantation (indications)	14
1.3 The molecular basis of rejection	16
1.4 Immunosuppression	18
1.5 Opportunities for graft specific treatments	21
1.6 Outcomes	22
1.7 Knowledge gap	23
<b>Chapter 2 – Pre-Clinical Models of VCA</b>	
2.1 Introduction	25
2.2 Principles of live animal pre-clinical research	26
2.3 Ideal model considerations	27
2.4 Swine gracilis model	28
2.5 Swine forelimb model	30
<b>Chapter 3 – Ischemia Reperfusion Injury and Autotransplantation</b>	
3.1 Introduction	33

3.2 Biomarkers of Ischemia Reperfusion Injury	34
3.3 C1-esterase inhibitor and ischemia reperfusion injury	35
3.4 Hydrogen Sulphide and ischemia reperfusion injury	36
3.5 Ex vivo tissue preservation and stabilisation	36
<b>Chapter 4 – Ischemia Reperfusion Injury, Targeted Immunosuppression and Allotransplantation</b>	
4.1 Introduction	39
4.2 Ex vivo perfusion, ischemia reperfusion injury and acute rejection following delayed replantation	39
4.3 Use of a hydrogel delivery system to delay the onset of acute rejection	40
<b>Chapter 5 – Conclusion and Future Direction</b>	42
<b>References</b>	44
<b>Appendices</b>	
1 - Institutional Animal Care and Use Committee Mandated Training	50
2 - Study 1	55
3 - Study 2	64
4 - Study 3	76
5 - Study 4	83
6 - Study 5	89
7 - Study 6	101
8 - Study 7	109
9 – Dr C A Fries contribution to studies	125
10 - Complete list of publications by Dr C A Fries	134
11 – Post – viva thesis addendum – future development of submitted papers	139


## Declaration

I, Charles Anton Fries, declare that:

(a) the submitted material as a whole is not substantially the same as published or unpublished material that I have previously submitted, or am currently submitting, for a degree, diploma, or similar qualification at any university or similar institution.

(b) that I have stated clearly which parts of the work or works submitted have previously been submitted for any such qualification; and

(c) where the work submitted includes work conducted in collaboration with others, I have provided a written statement on the extent of my individual contribution to the material and the conditions and circumstances under which the work was carried out. This statement has been signed by the lead/corresponding author for each of these works.



## Index of published works for consideration

Study number	Reference
1 (Appendix 2)	<i>Preclinical Models in Vascularized Composite Allotransplantation.</i> <b>C A Fries</b> , D W Tuder, M R Davis. Current Transplantation Reports 2015, DOI - 10.1007/s40472-015-0071-8
2 (Appendix 3)	<i>A Porcine Orthotopic Forelimb Vascularized Composite Allotransplantation Model – Technical Considerations and Translational Implications.</i> <b>C A Fries</b> , C Y Villamaria, J R Spencer, R F Rickard, V S Gorantla, M R Davis. Plastic & Reconstructive Surgery 2016 Sep;138(3):461e-471e doi:10.1097/PRS.0000000000002451
3 (Appendix 4)	<i>C1 esterase inhibitor ameliorates ischemia reperfusion injury in a swine musculocutaneous flap model.</i> <b>C A Fries</b> , C Y Villamaria, J R Spencer, T E Rassmussen, M R Davis. Microsurgery 2016 Apr 18. Doi: 10.1002/micr.30053
4 (Appendix 5)	<i>Hydrogen sulphide mitigates ischemia reperfusion injury in a porcine model of vascularised composite allotransplantation.</i> C Villamaria, <b>C A Fries</b> , J R Spencer, M Roth, M Davis. Ann Plas Surg 2014(May);72(5):594-598
5 (Appendix 6)	<i>A Hyperbaric Warm Perfusion System Preserves Tissue Composites Ex vivo and Delays the Onset of Acute Rejection.</i> <b>Fries C A</b> , Villamaria C Y, Spencer J R, Lawson S, Wang L, Raj T, Wolf E G, Parida B K, Gorantla V S, Rickard R F, Davis M R. J Reconstr Microsurg. 2018 Aug 12. 10.1055/s-0038-1667298
6 (Appendix 7)	<i>Composite Graft Pre-Treatment with Hydrogen Sulfide Delays the Onset of Acute Rejection.</i> <b>C A Fries</b> , S Lawson, L Wang, M Roth, R F Rickard, V S Gorantla, M R Davis Annals of Plastic Surgery: Jan (9) 2019 doi: 10.1097/SAP.0000000000001693
7 (Appendix 8)	<i>Graft-implanted, enzyme responsive, tacrolimus-eluting hydrogel enables long- term survival of orthotopic porcine limb vascularized composite allografts: A proof of concept study .</i> <b>C A Fries</b> , S Lawson, L Wang, J Karp, R F Rickard, V S Gorantla, M R Davis. PLOS_ONE <a href="https://doi.org/10.1371/journal.pone.0210914">https://doi.org/10.1371/journal.pone.0210914</a>

## Statement of candidate's contribution to published work

Contribution of the candidate	Corresponding author in agreement
<p>Study 1: Preclinical Models in Vascularized Composite Allotransplantation</p> <p>C Anton Fries (AF) identified the need to perform this literature review prior to starting on his programme of pre-clinical research. He was responsible for all aspects of the design and conduct of the review as well as writing and editing the manuscript.</p>	C A Fries ✓
<p>Study 2: A Porcine Orthotopic Forelimb Vascularized Composite Allotransplantation Model – Technical Considerations and Translational Implications</p> <p>AF and Michael Davis (MD) were responsible for the conceptualisation of the swine forelimb model of VCA. AF was responsible for protocol design, IACUC approval, all aspects of laboratory booking, staffing and equipment, performed the surgery and wrote, submitted and revised the paper.</p>	C A Fries ✓
<p>Study 3: C1 esterase inhibitor ameliorates ischemia reperfusion injury in a swine musculocutaneous flap model</p> <p>AF performed the surgery in conjunction with Carole Villamaria, collated results and wrote, submitted and revised this paper.</p>	C A Fries ✓

Study 4: Hydrogen sulphide mitigates ischemia reperfusion injury in a porcine model of vascularised composite allotransplantation

C A Fries ✓

AF performed the surgery in conjunction with Carole Villamaria, collated results and wrote, submitted and revised this paper.

Study 5: A Hyperbaric Warm Perfusion System Preserves Tissue Composites *Ex Vivo* and Delays the Onset of Acute Rejection

C A Fries ✓

AF, MD and George Wolf were responsible for the conceptualisation of this protocol, using a proprietary device of GW's invention. AF was responsible for protocol design, IACUC approval, all aspects of laboratory booking, staffing and equipment, performed the surgery and wrote, submitted and revised the paper.

Study 6: Composite Graft Pre-Treatment with Hydrogen Sulfide Delays the Onset of Acute Rejection

C A Fries ✓

AF and MD were responsible for the conceptualisation of this protocol. AF was responsible for protocol design, IACUC approval, all aspects of laboratory booking, staffing and equipment, performed the surgery and wrote, submitted and revised the paper.

Study 7: Graft-implanted, enzyme responsive, tacrolimus-eluting hydrogel enables long- term survival of orthotopic porcine limb vascularized composite allografts: A proof of concept study

C A Fries ✓

AF, MD and Vijay Gorantla were responsible for the conceptualisation of this protocol. AF was responsible for protocol design, IACUC approval, liaison with collaborators responsible for hydrogel production, all aspects of laboratory booking, staffing and equipment, performed the surgery and wrote, submitted and revised the paper.



## Acknowledgments

I am grateful to my mentors who have supported me through this journey from its inception. I would like to thank Dr Michael Davis and Surgeon Captain Professor Rory Rickard for their vision and insights in directing my scientific endeavours, their encouragement over the years and across continents, and their friendship.

I would like to thank Professor Joe Hardwicke and Dr Erin Greaves for directing me as I brought this body of work to its conclusion. I am grateful of their academic rigour in synthesising my papers into a coherent narrative, and steadfast attention to detail in the preparation of this dissertation.

I would like to acknowledge the men and women of allied forces whose sacrifices are beyond description. This work was conceived to improve their care. My greatest hope is that this may contribute to a more functional reconstruction, an improved outcome, or a better quality of life.

I would like to thank my mother for her love, patience, and relentless encouragement. Finally, I would like to thank Surgeon Commander Ed Barnard and Surgeon Commander Jowan Penn-Barwell for their inspiration, example, and support, along a road that goes on forever.

## Abbreviations

AALAS	American Association for Laboratory Animal Science
ADCC	Antibody Dependent Cell Mediated Cytotoxicity
APC	Antigen Presenting Cell
AR	Acute Rejection
AST	Aspartate Transaminase
C1-inh	C1 Esterase Inhibitor
CK	Creatine Kinase
CR	Chronic Rejection
CAD	Computer Aided Design
CAM	Computer Aided Modelling
EBV	Epstein-Barr Virus
H <sub>2</sub> S	Hydrogen Sulphide
HBO	Hyperbaric Oxygen Perfusion device
IL-6	Interleukin-6
IFN- $\gamma$	Interferon gamma.
MHC-2	Major Histocompatibility Complex Type 2
MMF	Mycophenolate Mofetil
NK	Natural Killer
IACUC	Institutional Animal Care and Use Committee
IRB	Institutional Review Board
IRHCTT	International Registry of Hand and Composite Tissue Transplantation
ISVCA	International Society of Vascularized Composite Allotransplantation
SLA	Swine Leukocyte Antigen
SOT	Solid Organ Transplant
TAC	Tacrolimus
T <sub>c</sub>	Cytotoxic T-Cell
THC	T-Helper Cells
TNF- $\alpha$	Tumour Necrosis Factor-alpha
TNF- $\beta$	Tumour Necrosis Factor Beta
VCA	Vascularized Composite Allotransplantation

## Prologue

During my 20-year career as a Medical Officer in the Royal Navy I deployed to Afghanistan twice and worked in the primary casualty receiving hospital in the UK.

I was struck by the advances in combat casualty care that enabled even the most severely injured personnel to survive. However, as a reconstructive surgeon I was frustrated by the inability of conventional plastic surgery to restore form and function in the face of these life-changing injuries. Reconstructive transplantation, or vascularized composite allotransplantation (VCA), is a potential solution for some of these patients. VCA enables like-for-like replacement of tissue deficits; hand and face transplants are exemplars of this technique.

Military conflict has driven medical advances since antiquity, in fields as diverse as infectious disease, vitamin deficiency, psychiatry and trauma. The modern surgical subspecialty of plastic surgery was itself born of World War I, when Sir Harold Gillies developed and disseminated reconstructive techniques to address the wounds of trench warfare. Step-changes occurred in the management of burns following the experience of Sir Archibald McIndoe treating downed airmen in World War II, and in the field of cleft surgery following Dr Ralph Millard's deployed work during the Korean War. In the conflicts of the early 21st Century advanced body armour, field resuscitation, rapid casualty recovery with *en route* critical care and deployed damage control resuscitation and surgery extended the envelope of survival. The burden of this survivorship was a cadre of injured personnel with multiple limb-loss, and severe maxillofacial and abdominoperineal injury.

VCA recipients must receive immunosuppressive treatment subjecting them to morbidity and mortality, hence the risk-benefit ratio of VCA is finely balanced. In an attempt to expand the applicability of this field for wounded servicemembers I embarked on a six-year research project, in collaboration with the United States Army Institute of Surgical Research in San Antonio, Texas. I developed and evaluated strategies to reduce the toxicity of immunosuppression. This involved four years of laboratory work, from which seven peer-reviewed papers were subsequently published.

Each protocol was a stand-alone study designed to test a specific hypothesis. However, taken together, they represent the development of the overarching hypothesis of my program; that targeted, graft-specific, immunomodulation strategies could prevent acute rejection of VCA grafts, whilst reducing the exposure of patients to drug toxicity.

# Chapter 1 – Introduction to Vascularized Composite Allotransplantation

## 1.1 Introduction

Vascularized Composite Allotransplantation (VCA) refers to the transplantation of a part of the human body, from a deceased donor to a living recipient who has suffered loss or irrevocable damage of the corresponding part<sup>1</sup>. Most commonly this is of the hand or face. Such transplants are also referred to as 'reconstructive transplants', as they form part of the reconstructive surgeons' armamentarium to treat functional loss. They differ to more common solid organ transplants (SOT), as multiple tissue types are transplanted. VCAs are 'composites' of tissue types such as skin, bone, muscle, tendons and nerves, as opposed to being a single organ of more uniform cell types. They also differ from solid organ transplantation in that they are not performed to treat life-threatening organ failure, but to improve the patients function and quality of life. Put simply; a patient with total liver failure will die without a liver transplant, however a patient with bilateral hand amputation may have a 'normal' life expectancy, but require around the clock support with feeding, toileting and other self-care. Thus, subjecting such a patient to lifelong immunosuppression with attendant morbidity and mortality is a complex decision. However, the concept of 'normalcy' with respect to life-expectancy in such patients is open to debate. The natural history of bilateral hand loss, or facial disfigurement of such severity that a face transplant might be considered, may well predispose to joblessness, social exclusion, depression, substance dependency and even suicide<sup>2</sup>.

Initial challenges in VCA surgery focussed on the technical difficulties of this work. Operations required teams of surgeons from multiple specialties working for over 24 hours using microsurgical skills to reattach blood vessels, nerves and tendons as well as bony components of the facial skeleton or forearm. However, having achieved technical successes in completing the operations, determinants of long-term outcome have come to focus on the immunological suppression regimens required to prevent immunological rejection, and the psychological preparedness and adaptation of the patient themselves to prevent psychological rejection.

The intricacy of the human hand is a marvel of evolution that is inextricably linked with the elevation of the species itself. Described as an 'extension of the brain', the prehensile, sensory, aesthetic and social functions of the hand defy recreation by prosthetic alternatives<sup>3</sup>. Replacing the hand by conventional reconstructive surgical means is impossible. The use of the operating microscope to perform vascular anastomosis, the joining in continuity of two hollow viscera or vessels, in small, distal blood vessels was first described in 1960, and the first replantation of an amputated digit in 1965<sup>4</sup>. The stage was thus set for the epistemological leap from replantation to transplantation of the hand, to treat patients who had suffered total hand loss. The first hand transplant of the modern era was performed in Ecuador in 1964, but with only rudimentary immunosuppression the allograft was lost in the early post-operative phase<sup>5</sup>. The first hand transplant to be performed with modern immunosuppression and achieve durable success was performed in France in 1998<sup>6</sup>.

Such transplantation of functional tissue composites, tissue blocks supplied by defined neurovascular territories, could in theory be extended to any area of the body. However, the requirement for lifelong immunosuppression with attendant risks of morbidity and mortality meant that such transplants could only be considered in situations where the benefits might reasonably be expected to outweigh these risks<sup>1,7-9</sup>. For example, whilst lower limb transplantation has been attempted to treat lower extremity amputation, the generally excellent rehabilitation achieved with the use of prosthetics has meant that this remains a rarely indicated and controversial procedure<sup>10</sup>. Conversely, a transplant of abdominal tissue from an identical twin was used to reconstruct her sister's back in a case of recurrent sarcoma, the excision of which resulted in a large defect that could not otherwise be skin grafted. No immunosuppression was required due to their being identical twins, and, despite the donor sister did have to undergo the risks of surgery, she effectively received a cosmetic excision of excess abdominal tissue.

The face, like the hand, defies conventional reconstruction and its functional role is so significant that allotransplantation can be considered a potential treatment. The first face transplant was performed, also in France, in 2005<sup>11</sup>. Since then at least 130 upper limb and 40 craniofacial transplants have been performed, with 20-year follow-up in some cases<sup>12</sup>. Subsequently, the field has expanded to include abdominal wall, lower limb, uterus, penis,

scalp, neck organs, larynx, and sentinel skin flap transplants for immunologic monitoring of solid organ transplants. Assessing outcomes has been challenging, *vide infra*; however, the re-amputation of the first hand transplant after only two years, following psychological rejection of the limb and non-compliance with immunosuppression, is said to have set the field back by years. Conversely, the wonderful success of the world's second hand transplant, who enjoys good function 20 years after the fact and staunchly advocates for the procedure, has been hard to replicate. To date all VCA transplants have been performed as experimental treatments under Institutional Review Board supervision, although it is argued that double hand transplantation may be considered the standard of care treatment for bilateral hand loss<sup>13</sup>.

## **1.2 Conditions considered suitable for treatment by Vascularized Composite Allotransplantation (indications)**

The first VCAs were performed due to traumatic limb or tissue loss. The reactivation of malignancy or sepsis secondary to immunosuppression or adding to the immunologic burden of a patient by combining a VCA with an SOT were considered relative contra-indications. Risks of reactivating latent infection in, for example, military patients with retained foreign bodies or post-sepsis cases of multiple limb loss have proven unfounded as the field has expanded<sup>14</sup>. Similarly, cancer survivors whose potential gain in function has been deemed to outweigh the possible risks of recurrent malignancy have been treated by transplantation. Finally, it has been found that rates of rejection in combined VCA and solid organ cases have been similar to those in organ-only transplant recipients<sup>15</sup>.

Hand and face transplants remain the most commonly performed VCAs. In addition, to date 35 full thickness abdominal wall transplants have been performed internationally<sup>16</sup>. Most commonly these are in combination with a multi-visceral transplant, often involving the small intestine, where it is no longer possible to primarily close the abdominal domain. In this situation the risk benefit of the VCA is improved as the patient will already require lifelong immunosuppression for their life-saving visceral transplant. Hitherto the addition of the skin containing VCA has not led to significantly increased rates of rejection, and these cases deliver rich information on the interplay between SOT and VCA immunology. The observation

that visible rejection in the skin of the abdominal wall may herald rejection in the, immunologically identical, transplanted viscera beneath is particularly exciting and has led to clinical trials analysing the use of distant sentinel VCA flaps in SOT patients<sup>17-19</sup>. Four penile transplants have been performed worldwide, due to sepsis following ritual circumcision in three cases and malignancy in one. Return of sexual function has been achieved and one pregnancy reported<sup>20</sup>.

Similarly to the situation of the abdominal wall cases, patients who are systemically immunosuppressed due to pre-existing SOT may be suitable for more novel VCAs, as the risk of additional immunosuppression is the same or only slightly elevated by the additional transplant. Such cases have included the *en bloc* transplantation of the anterior neck organs, including functioning larynx, trachea, thyroid and parathyroid glands in a patient with laryngeal squamous cell carcinoma who had had a previous renal transplant<sup>21</sup>. He was successfully weaned from his tracheostomy and percutaneous feeding and was able to maintain normal endocrine homeostasis. Finally, the world's first paediatric hand transplant was performed in a seven-year-old boy who had already undergone a renal transplant. He had lost his kidneys at the same time as all four of his limbs due to meningococcal sepsis<sup>22</sup>.

Advances in microsurgery and anaesthetic safety have enabled highly complex transplantations to be performed. In particular the use of computer aided design (CAD) and computer aided modelling (CAM) has extended the envelope of feasibility in the case of maxillofacial VCAs requiring elements of the facial skeleton to be transplanted. At this time the risks of immunosuppression remain the greatest obstacle to the technical feasibility of VCAs, although the psychological acceptance of the transplanted tissue has also proven to be a significant predictor of long-term outcome<sup>2</sup>.

Despite most programs engaging patients in rigorous pre-surgical screening and counselling a number of VCAs have been 'psychologically rejected', leading to the re-amputation of grafts and non-compliance with immunosuppressive drug regimens<sup>23</sup>. History of self-harm, drug use, and the recipient's options for social and work reintegration, as well as family or social support must be considered. Despite these caveats, face transplants have achieved enduring success in selected cases of self-inflicted gun-shot wounds to the face, for example.



In summary; patients must be able to not only fully engage with the intensive rehabilitation programs but also comply with immunosuppressive medication regimes.

### **1.3 The molecular basis of rejection**

The recognition of transplanted material as 'foreign' and its rejection and destruction is a complex process involving both the innate and adaptive immune systems. The T cell is central to both processes and is responsible not only for recognition of the donor derived antigens, but also the proliferation of effector cells able to achieve graft cell destruction. Cells of the innate immune system include neutrophils, mast cells, dendritic cells, macrophages, natural killer cells. These cells have the ability to destroy allograft tissues directly by phagocytosis (monocytes / macrophages) or perforin mediated cell lysis (natural killer cells), and also to augment the adaptive immunity, in particular by interaction with T cells. The complement system also forms part of the innate immune system.

The major histocompatibility complex class 2 (MHC-2) molecule is preferentially expressed on antigen presenting cells (APC) such as dendritic cells, macrophages, B cells, activated T cells and the vascular endothelium. Dendritic cells are particularly prevalent in skin, a suggested molecular basis for the observed high antigenicity of skin containing VCAs. The variability of the number of APCs in different tissue types is the basis of so-called 'split tolerance', whereby different components of VCA transplant appear to undergo immunologic rejection at different rates or severity<sup>24</sup>. Antigen presenting cells present antigen to CD4 positive T-Helper cells (THC) via their MHC-2 molecules, thus activating the THC. This triggers a cascade of events including cytokine release, cloning of the activated THC, further cytokine production leading to the production of CD8 positive cytotoxic T cells and B cells, and activation of macrophages. Cytokines implicated include Interleukins-2, 4, 5, 6, Interferon gamma and tumour necrosis factor-beta (see figure 1).

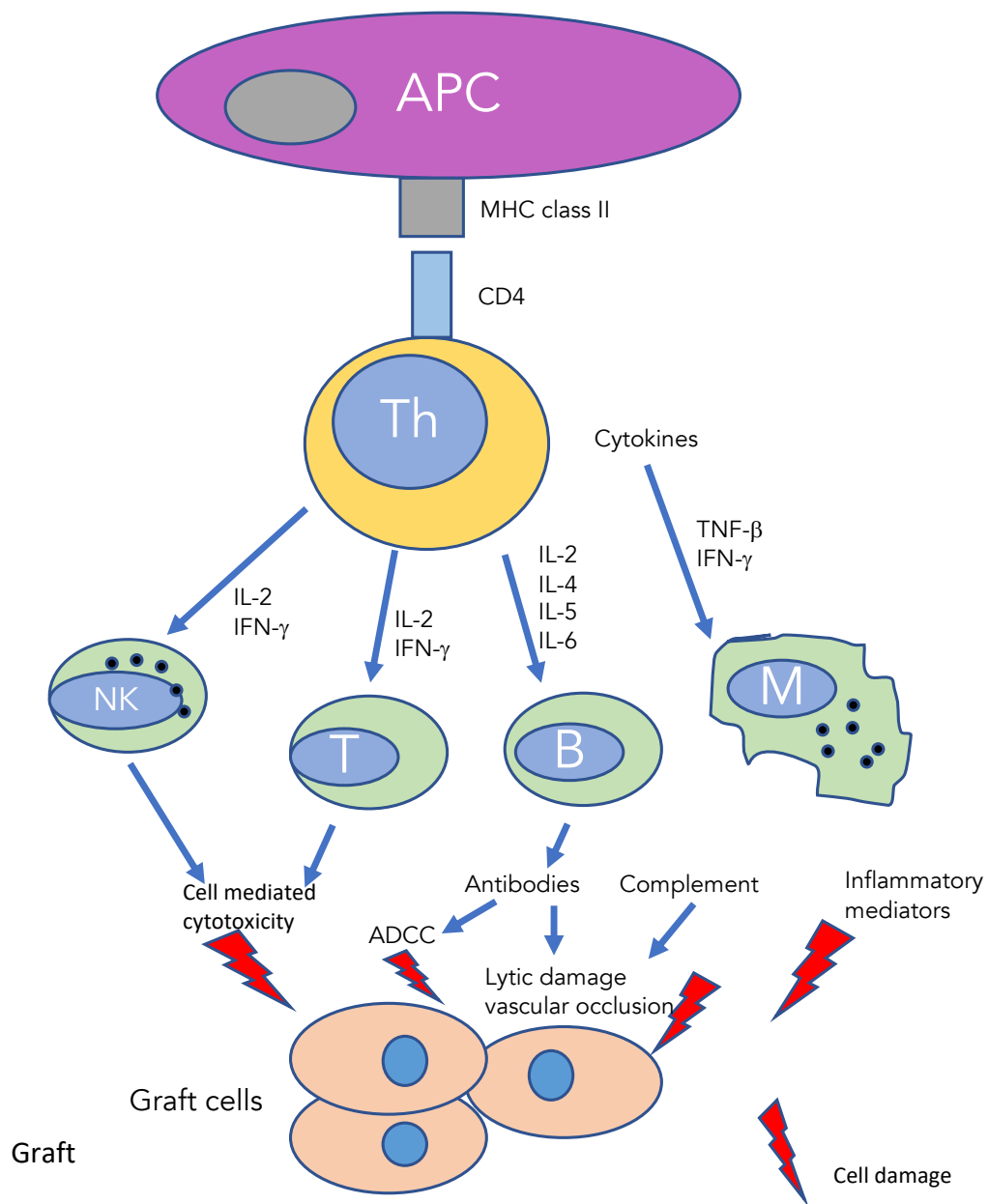


Figure 1: The molecular basis of acute rejection (adapted from Immune Responses in Transplantation: Application to Composite Tissue Allograft Aleksandra Klimczak, Ph.D., and Maria Siemionow, M.D., Ph.D., D.Sc.)<sup>25</sup>. ADCC – Antibody Dependent Cell Mediated Cytotoxicity, NK – Natural Killer, Tc – Cytotoxic T-Cell, B – B-Cell, M – Macrophage, APC – Antigen Presenting Cell, MHC – Major Histocompatibility Complex, Th – T Helper Cell, IL – Interleukin, TNF-β Tumour Necrosis Factor Beta, IFN-γ Interferon gamma.

## 1.4 Immunosuppression

The utility and wider application of VCA is constrained by the risks of systemic immunosuppression that confer morbidity and mortality to transplant recipients<sup>26</sup>. In solid organ transplantation this risk is offset by the life-saving properties of the transplanted organ; a patient with renal failure dependent on dialysis will have a shorter life expectancy than one who receives a kidney transplant, despite the toxicity of the immunosuppression<sup>27</sup>. In the case of VCA however, life expectancy is reduced. Indeed, several VCA recipients have now died, in both the acute and later stages following transplantation, from complications relating to immunosuppression<sup>28</sup>.

All VCA patients have suffered episodes of acute rejection (AR), and 80% suffered acute rejection in the first year following transplantation<sup>29</sup>. This contrasts with rates as low as 10% in well matched renal transplants. The skin is the most immunogenic tissue type in the body, thus VCA transplants are particularly susceptible, indeed the phenomenon of 'split tolerance' whereby AR has been observed in the skin but not deeper tissue has been observed. As the field has developed episodes of chronic antibody mediated rejection (CR) have been recognised, leading to graft loss and, in two cases, re-transplantation<sup>30</sup>.

Whilst CR has affected the skin, manifest by changes similar to those seen in scleroderma, i.e. a continuous rash has developed; the most deleterious effect on the whole graft has been by means of vasculitic effects. The lumen of the small blood vessels of the transplant graft have been narrowed leading to distal ischemia of the tissues<sup>31</sup>. The latter mirrors the situation in SOT and is understandably similar to auto-immune diseases where the body's own immune system attacks the tissues.

Side effects of systemic immunosuppression include neoplastic, infective, endocrine and metabolic disorders. Epstein-Barr Virus (EBV) related post-transplant B-cell lymphomas, squamous cell carcinomas (particularly of the skin), lung, colon and non-hodgkin lymphoma have occurred. Bacterial infections and opportunistic infections have been observed. Steroid therapy induced diabetes mellitus and osteopenia have led patients to require insulin therapy and joint replacements respectively. Nephrotoxicity, secondary to Tacrolimus (TAC), a

calcineurin inhibitor and the most used anti-rejection medication, has led to patients' needing renal replacement therapy<sup>28</sup>.

Drug regimens have closely mirrored those utilised in solid organ transplantation. Induction therapy at the time of transplantation is followed by continuous maintenance therapy. The latter is titrated over time; being increased in response to episodes of rejection or reduced in response to medication side effects. In contradistinction to solid organ transplants, VCA transplants containing visible skin components offer the chance of visual monitoring of rejection and topical application of immunosuppression. Topically applied immunosuppression has shown promise based on the 'split tolerance' effect, however where deeper structures are involved this may mask the true immunologic picture. Finally, acute episodes are treated by medication boluses – so-called 'rescue therapy'<sup>9,32</sup>.

According to the report of the International Registry of Hand and Composite Tissue Transplantation (IRHCTT) of 2017, induction regimes in VCA transplants were based on anti-thymocyte globulins (57.9% of cases) (alemtuzumab, basiliximab and dalizumab)<sup>33</sup>. Induction regimens are designed to reduce levels of circulating lymphocytes (B and T cells) immediately prior to transplantation. Such depletion cannot be safely sustained in the longer term, however it creates a window of opportunity to complete the transplant with a reduced immune response, and reduced rates of hyper-acute and acute rejection. Maintenance therapy showed strong concordance, with tacrolimus (94.8%), mycophenolate mofetil (MMF), an inhibitor of B and T cell proliferation (91.2%), and steroids, acting to sequester T cells (87.5%), being the mainstays of treatment. Attempts to withdraw or reduce to single agent therapy have been found to be mostly unsuccessful. Acute episodes were treated with steroid boluses, both intravenous pulse therapy and increases in oral dosing, and anti-thymocyte globulins in steroid resistant cases. Figure 2 shows the site of action of the anti-rejection drugs described above.

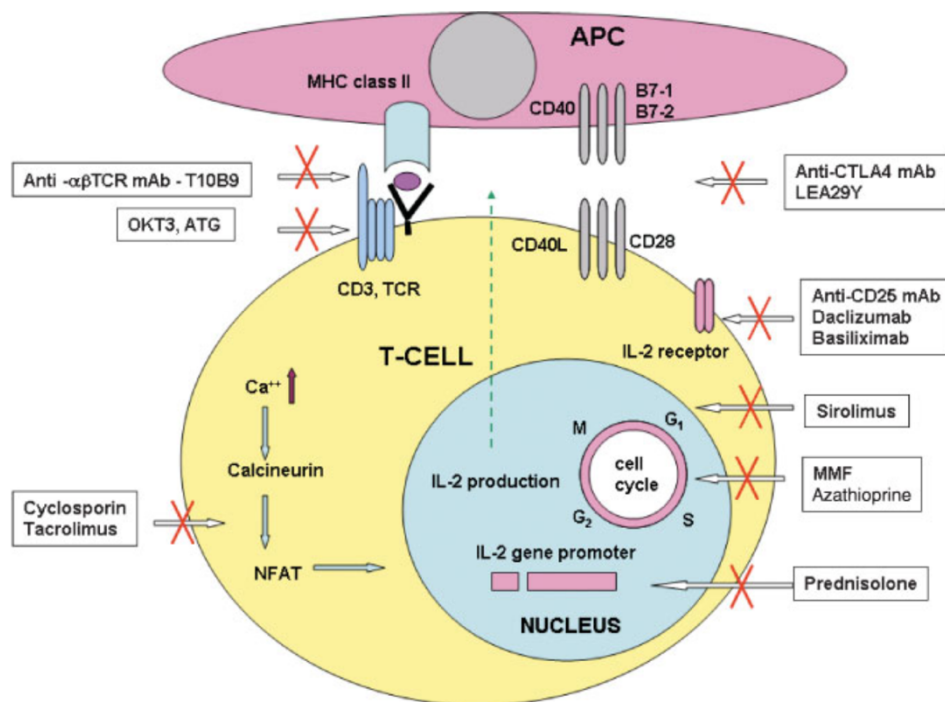


Figure 2: Sites / mechanisms of action of currently used ant-rejection medications (adapted from Immune Responses in Transplantation: Application to Composite Tissue Allograft Aleksandra Klimczak, Ph.D., and Maria Siemionow, M.D., Ph.D., D.Sc.)<sup>25</sup>.

Various strategies to reduce the toxicity of immunosuppression have been evaluated by the international VCA research community. Attempts to induce tolerance, establish chimerism, the use of steroid-sparing drug regimens and cellular therapies have achieved some successes in the pre-clinical arena. Despite this work the mainstay of immunosuppression in clinical VCA remains systemic 'triple therapy', i.e. prednisolone, tacrolimus and mycophenolate mofetil, based on solid organ transplantation protocols<sup>34</sup>. Finally, notwithstanding the limitations of current regimens even under idealized conditions, several treatment failures have occurred due to patient non-compliance with immunosuppression. This was the cause of the loss of the very first hand transplant itself. Reasons for non-compliance may be due to individual factors and 'psychological rejection' of the transplant, the burden of side-effects not being worth the benefit of the transplant, or due to resource limitations on the part of the transplant programs.

### **1.5 Opportunities for graft specific treatments**

The VCA transplant, like all organ transplants, is both the stimulus for, and the subject of, the immune response. As such, it is intuitive that manipulating the graft itself in some way may partially obviate the cause or effects of AR. In addition to the presentation of foreign immunologic material, the act of transplantation causes an inflammatory milieu due to the obligate ischemia reperfusion injury (IRI) at the time of transplantation<sup>35</sup>. This IRI occurs at the time of re-establishment of circulation on the recipient, following a period of anaerobic metabolism and build-up of metabolites and inflammatory cytokines that occurs from the time of detachment from the donor circulation<sup>35</sup>. Once circulation is restored there is a paradoxical exacerbation of cellular dysfunction in the transplanted part, and distribution of the deleterious compounds in the recipient. In the most extreme cases, for example reperfusion of large muscle compartments following crush injuries, IRI can cause death; therefore, early fasciotomy and even acute amputation are appropriate treatments in such cases. Increased IRI, due to extended ischemia times prior to transplantation, has been shown to be an independent predictor of poor graft function and increased rates of AR in renal transplantation<sup>34,35</sup>.

As VCA transplants are partially visible, with surface skin components and oral epithelial components in some cases, there are two opportunities to apply such manipulations or therapies. First during the ischemic period itself when the graft is detached, and secondly after the transplant has been performed and the visible skin component of the VCA is available to topical treatment. The manipulation of the graft either to reduce its direct immunogenicity or reduce the IRI at the time of transplantation may be hypothesized to reduce rates of immunologic rejection<sup>36</sup>.

## 1.6 Outcomes

Despite these concerns, many hand amputees who were totally dependent for all aspects of daily care, including feeding and toileting, and patients who were socially excluded due to facial disfigurement, have chosen to accept these risks and undergo life-enhancing transplants. Indeed, it has been suggested that for a bilateral hand amputee a double hand transplant should be considered the standard of care<sup>13</sup>. Outcome data on international VCAs is incomplete. This represents a significant challenge to the community of physicians and scientists who pursue this field, the more so as, by their nature, VCAs are highly heterogeneous and performed in low numbers in all but a few centres.

In the worldwide literature 120 hand transplants have been published in 74 patients. Overall outcomes have been good with the majority showing improved function compared to the use of upper limb prosthetics, particularly in psycho-social domains<sup>37</sup>. More distal transplants have shown improved functional returns as the intrinsic muscles of the hand are more likely to be reinnervated, however recipients of more proximal transplants have potentially more to gain from their baseline state. Significantly, rates of loss, including from psychological rejection and non-compliance with medications, have been greater in the unilateral cases. This reflects the relatively stronger indication to perform transplantation in cases of bilateral hand loss, and speaks to the potentially unacceptable burden of therapy and immunosuppression required to maintain a single hand transplant in conjunction with a normally functioning contralateral limb. Combined graft survival in American and European centres is 90%<sup>33</sup>.

To date there have been approximately 40 face transplants performed of whom nine are known to have died and two have received re-transplantation as the result of chronic rejection (at seven and eight years post the original transplants, respectively). Deaths were most commonly in the early postoperative stages and in combined hand and face VCAs. Delayed deaths have occurred at 11- and 12-years following transplantation because of malignancy and infection respectively. Most patients have reported acceptable functional and aesthetic outcomes.

## 1.7 Knowledge gap

In conclusion, VCA is a powerful technique that has benefitted many patients across the globe and has the potential to deliver life-changing results in reconstructive surgery. At this time however, it can be characterised as being high risk / high reward; whilst some patients have benefitted from long term improvements in function, an important minority have suffered from significant medication side effects, graft loss and even death. VCA remains an experimental technique performed in only a few centres, under research licences. For this field to expand, and more patients to benefit, further research is mandated to enhance the risk-benefit ratio. Whilst there are many aspects where improvements can be achieved, including psychological screening and therapy, graft procurement and preservation techniques and intra-graft nerve regeneration; the most significant barrier is the toxicity of systemic immunosuppression.

The nature of the graft as both initiator and subject of acute rejection and IRI suggests that treating the graft itself prior to transplantation to reduce either of these phenomena might enable reduced immune rejection. Developing a model to test this hypothesis, utilising a device to extend the window of opportunity to so manipulate the graft, and testing hitherto untried therapies to reduce IRI and antigen presentation by the graft itself were all areas included in my investigation.

This PhD submission encompasses the output of six years' work investigating techniques to address this problem. The overarching theme of which was to target the graft itself rather than the patient as a whole, and thus reduce systemic exposure and toxicity.



There were four aims:

1. Develop advanced preclinical models of VCA.
2. Evaluate and ameliorate the Ischemia Reperfusion Injury of transplantation.
3. Achieve ex vivo tissue preservation and stabilisation.
4. Deliver targeted, graft-specific, immunosuppression.

## Chapter 2 – Pre-Clinical Models of VCA

### 2.1 Introduction

Despite being a clinical reality for 22 years, vascularized composite allotransplantation (VCA) remains an experimental procedure with significant barriers to its wider application. Chief among these is the morbidity and mortality associated with systemic immunosuppression. Current immunosuppression strategies are informed by translation of best practice from the field of solid organ transplantation (SOT). Despite significant efforts by the international VCA community, no bespoke strategy for VCA transplants has reached routine clinical practice. The significant differences between VCA and SOT have not been leveraged to yield improvements in the field of VCA, nor have potential concerns, for example split tolerance and differential rates of chronic rejection, been definitively addressed. The immunogenicity of the skin, wide range of tissue types simultaneously transplanted, and susceptibility of the exposed graft to environmental insult causing episodes of rejection, are challenges unique to VCA. Conversely, the potential for real-time visual monitoring of skin containing transplants, relative ease of topical application of immunosuppression, and chimeric effects of bone-marrow containing VCAs, are potential opportunities not available in the SOT arena.

The heterogeneity of transplants and the relatively low numbers of cases performed confound clinical research efforts. The majority of centres performing VCA have fastidiously recorded and reported their outcomes, conscientiously contributing to the scientific discourse of the field. The International Registry of Hand and Composite Tissue Transplantation (IRHCTT) and International Society of Vascularized Composite Allotransplantation (ISVCA) have collated, analysed and discussed clinical techniques and outcomes, as well as pre-clinical, including animal, research. The latter enables ethical, safe, reproducible and translatable investigation into the unique issues surrounding VCA immunology. The ability to standardise practices, control for confounders, and perform procedures at a large scale is not possible in human subjects<sup>38</sup>. Clinical trials in surgery are by their nature challenging to devise, even more so in areas where cases are rare. That being said, inter-species differences can hamper generalisability and the resource requirements for conducting such work can be very high.

This is especially the case in the use of large animals, or higher species, which have exacting husbandry requirements.

The principles of 'reduction, replacement and refinement' are paramount in such research. As I embarked on the development of a gold-standard model to enable the most effective translatability and yield the greatest benefit to the field of VCA, an exhaustive review of the existing literature was performed. The findings of this review were published in the paper at Appendix 2<sup>39</sup>. In the research presented in this thesis I used two models; whilst developing the swine forelimb model I used and refined the previously described swine gracilis muscle flap VCA model<sup>40,41</sup>. The use of these two models illustrated several of the competing principles inherent in pre-clinical research. For example, the gracilis muscle transplant could be performed at relatively large scale and with reduced logistic requirements compared to the forelimb transplant, however the forelimb delivered a higher fidelity of result<sup>42</sup>.

## **2.2 Principles of live animal pre-clinical research**

The principles of reduction, replacement and refinement underpin contemporary approaches to the use of animals in research. In summary, animal research protocols seek to use the minimum number of animals required to address the hypotheses being tested (reduction). Where possible the use of live animal subjects should be avoided altogether, for example if simulation or computer modelling can be used as an alternative (replacement). Finally, experiments must be designed with rigorous attention to the welfare of the subjects; including the avoidance and alleviation of pain and suffering, environmental enrichment, and humane euthanasia as required (refinement). Such work is overseen by the Institutional Animal Care and Use Committee (IACUC) whose role is to ensure best practice and regulatory compliance.

Prior to embarking on development and implementation of the pre-clinical models I underwent appropriate training. A complete list of courses completed by the author is presented at Appendix 1.

### 2.3 Ideal model considerations

Animal models for experimental research must be ethical and be able to deliver translatable results. Properties such as anatomic and physiologic similarity to humans, generalisability, reproducibility, and resource requirements for husbandry, are relative and must be balanced by the research group to best address their hypothesis. For example, the use of small animals such as mice are relatively inexpensive with respect to housing and husbandry, however their anatomy is distinct from the human. Conversely non-human primates have very similar anatomy to the human, however resource requirements are orders of magnitude higher. In general, small animal models are most suited to answer questions of mechanism and pathway, and large animal models for patient safety, surgical feasibility and generalisability.

Models of transplantation may be either heterotopic; where the transplanted graft is re-implanted to an anatomic location on the recipient that is different from its usual location, or orthotopic, where the transplanted graft is transferred to its normal anatomic location. The former situation may be technically more feasible, or reduce husbandry requirements, for example by preventing self-mutilation. However, in most cases an orthotopic transplant will deliver more translatable functional information. Models of allotransplantation; where the transplanted organ or tissue is procured from a donor and transplanted to a separate recipient of the same species, can also be used to perform auto-transplantation. In this case the organ or tissue is transplanted to a different (i.e., heterotopic) location on the same donor animal. In this case there is no immune rejection phenomena, however surgical technique, feasibility and the effects of ischemia reperfusion injury can be studied.

A detailed review of animal models used in VCA was performed and is included at Appendix 2. In summary, at the time of publication, 29 different models of VCA in nine species had been described in the global literature. Eleven were in rats, mice or rabbits and the remaining 18 in large animals including canines, swine and non-human primates. My review paper has been cited six times in the peer reviewed literature.

## 2.4 Swine gracilis model

The swine gracilis model was first described in 2012 by our group, and also by Barone et al in Boston. The latter team used a slightly different surgical approach<sup>40,41</sup>. This model became a workhorse for our team over the next three years. A detailed description of the surgical steps is provided in the publications at Appendices 4-7. The model involves the retrieval of the gracilis muscle and overlying skin from the hindlimb of the animal as a tissue composite supplied by a single artery and vein. This is a standard 'free-flap' as used in human clinical practice. The musculocutaneous flap can then be replanted into the neck of the same animal (autotransplantation) or a different recipient (allotransplantation). The carotid and jugular vessels in the neck are used as recipient vessels, and the skin sutured into a visible location in the animal's anterior neck.

This model is extremely reliable, it has consistent anatomy, relatively large calibre vessels and, aside from basic wound care, minimal husbandry requirements. Surgeons with microvascular training can achieve excellent, reproducible, results. The total operative time is around two hours in experienced hands which minimises anaesthetic duration for the subjects and maximises efficiency from the laboratory perspective. The position of the transplanted flap and the donor wound cause no functional restriction to the animals, who tolerate the procedure well. Subjects can freely ambulate following the operation, the flap can be visually monitored, and self-mutilation is not possible. During the allotransplantation phase of these protocols (Appendices 6 & 7) it was routine to perform six or eight gracilis allotransplant procedures per week. Figure 3 shows a schematic of the gracilis flap allotransplant procedure.

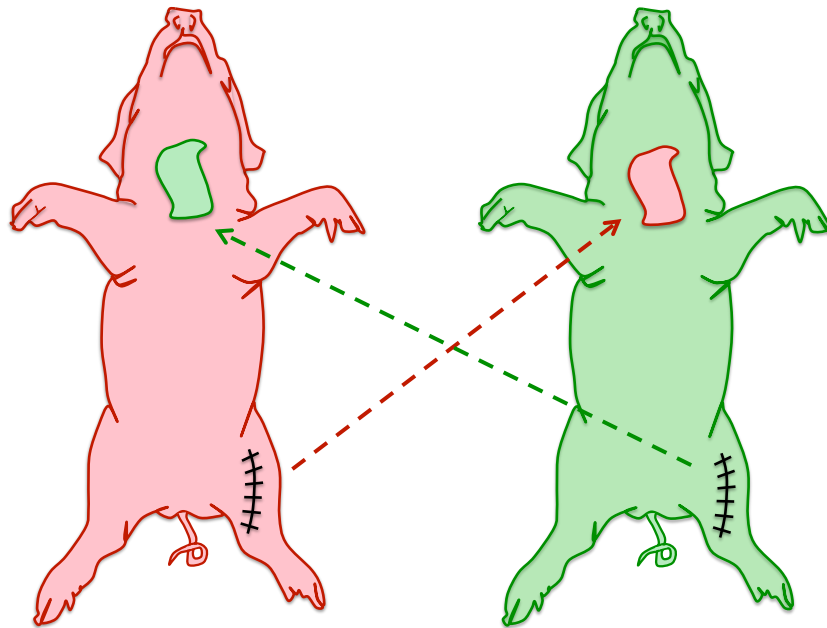


Figure 3: Schematic of gracilis flap allotransplant procedure: the musculocutaneous flap is raised from the left hindlimb of each animal and transplanted to the neck of the recipient. Each animal is donor and recipient of flap transplant.

The gracilis flap tissue composite contains muscle and skin. The latter is considered the most significant tissue type transplanted in VCA, *vide supra*. In this model an area of insensate transplanted skin can be biopsied at required intervals to study the progression of skin rejection histopathologically (see Chapter 4). The inclusion of muscle enables analysis of the effects of ischemia reperfusion injury as this is the most susceptible tissue to periods of ischemia. Thus, this model is able to provide immunological information on skin rejection and the contribution of IRI to acute rejection. However, there is no ability to study functional recovery of tissues in this heterotopic position. There is no bone component, which is not only ubiquitous in upper limb transplants and many maxillofacial transplants, but is also implicated in modifying the immune response. The heterotopic position and absence of functional nerve coaptation eliminates this area of investigation; nerve regeneration in hand and face transplantation is the critical determinant of long-term functional recovery, following successful revascularization of the graft.

## **2.5 Swine forelimb model**

Whilst recognising the efficacy of the gracilis model, it was clear that with our institution's experience and expertise in animal care it might be possible to perform more complex transplantation procedures, yielding greater information than available from the musculocutaneous flap. An orthotopic limb transplant had hitherto not been performed in swine, due to concerns about the ability of the animals to ambulate post-operatively, and the potential for self-mutilation of the insensate transplanted limb. Unpublished reports from one group had suggested that it had not been possible to reliably fix the transplanted bone to the recipient position. Transplanting the forelimb at the anatomic level of the mid forearm resulted in a transplanted graft that included skin, bone, muscle, tendons and neurovascular structures. This enabled the study of split tolerance as well as any effect of transplanting a vascularized bone marrow component on the immune response. The orthotopic position of the limb allowed the assessment of functional recovery in terms of the animals' ability to ambulate post-operatively. Finally, performing the repair of the median nerve in the forelimb enabled the neurophysiological and histological evaluation of nerve recovery. The latter is a critical determinant or outcome, as well as being the subject of intense research interest regarding the possible beneficial effects of tacrolimus therapy on nerve regeneration.

The development of this model is described in detail in Appendix 3<sup>42</sup>. In summary, an iterative process of model design was undertaken; starting with post-mortem anatomic specimens and progressing through stages of auto-transplantation (i.e., replantation), auto-transplantation with extended survival periods to establish long term feasibility, and then allotransplantation. Despite intense activity and institutional support, it took 18 months to move from initial planning stages to being able to perform reliable allotransplants.

Significant technical surgical challenges included gaining reliable orthopaedic fixation of the transplanted bone, achieved by using a double plate fixation, and revascularization of the graft, by shortening the bone slightly and transposing vessels to reduce tension on the repair. Thromboprophylaxis treatment was introduced, as well as long term antibiotic and analgesic regimens. Attaching of surgical cast to the limb by pinning it in place was another refinement.

Post-operative care was very challenging. In the immediate post-operative phase correctly maintaining the position of the animal's limb to protect the delicate surgical anastomosis was critical. As the time after surgery progressed, enabling the animals to recover mobility and self-care was more important. A wheeled sling system was abandoned as the animals did not tolerate it. It was found that nursing them slightly sedated in a lateral position achieved the best outcome. Dietary modifications were made to maintain the animal's weight and the protocol of post-operative biopsies adjusted to prevent too many episodes of sedation in the immediate post-surgical phase.

Despite these difficulties it became possible to perform up to four such transplants per week with reliable outcomes. Having designed this model, it was then used to test the tacrolimus hydrogel system and evaluate its effect on acute rejection. This protocol was published and included at Appendix 7 and discussed in further detail in Chapter 4. Having completed this work, the model was used in as yet unpublished work where neurophysiological tests were performed on the transplanted nerve.

The publication of the model has been cited eight times in the peer reviewed literature and the review paper six times. In each case there have been positive reflections on the multiple tissue type composition, load-bearing nature and potential to study nerve regeneration. Despite its continued use at the United States Army Institute of Surgical Research at San



Antonio, no other group has used this model routinely in their investigations. This may reflect the fact that the demands of technical support remain high in contrast to other, heterotopic, options in large animals.

## Chapter 3 – Ischemia Reperfusion Injury and Autotransplantation

### 3.1 Introduction

The second aim of this work was to characterise and ameliorate the ischemia reperfusion injury (IRI) at the time of transplantation. This was to test the hypothesis that IRI is a contributing factor to acute rejection phenomena, and that treatments directed at reducing this could prevent, delay, or reduce the severity of, acute rejection.

At the time of tissue transplantation there is an obligate IRI as vascular perfusion to the transplanted tissues is interrupted before being re-established. This occurs both in autotransplantation, such as free-flap reconstruction, or allotransplantation, such as organ or vascularized composite allotransplantation (VCA). The restoration of circulation to temporarily ischemic tissues creates an inflammatory milieu that is deleterious to both the transplanted tissue (graft or flap) and the recipient (host). At the extremes this can result in the immediate loss of the tissue due to a 'no-reflow' phenomenon, or even the loss of life of the patient from complications of myoglobinaemia following delayed revascularisation<sup>35,43,44</sup>. Consequently, all transplant programs take steps to ameliorate this phenomenon by reducing the ischemia time as far as possible, and by optimising the storage of the graft during the ischemic period. This optimization typically involves cooling the graft, to reduce the metabolic demand of the tissue, and the use of a preservation solution that further reduces tissue damage. In solid organ transplantation (SOT) increased severity of the IRI has been shown to translate to earlier and more frequent episodes of acute rejection (AR). In turn, the number and severity of episodes of AR directly relates to a reduction of graft function, development of chronic rejection (CR), and eventual graft loss. It is therefore hypothesised that a reduction in IRI at the time of transplantation may have beneficial immunological effects, leading to improved graft function and reduced rates of graft loss in VCA<sup>36</sup>. I investigated three strategies directed at reducing the IRI of transplantation; the targeted delivery of C1 Esterase Inhibitor to the transplant, the targeted delivery of Hydrogen Sulphide to the transplant, and finally, supporting the transplanted tissue *ex vivo* using a hyperbaric oxygen chamber and perfusion circuit (HBO) prior to transplantation.

### 3.2 Biomarkers of Ischemia Reperfusion Injury

Cessation of oxygen supply to tissues results in anaerobic metabolism, depletion of cellular adenosine triphosphate, lactic acid accumulation, reduction in pH, impairment of cell membrane transport and mitochondrial swelling; leading to release of pro-apoptotic proteins. The re-establishment of circulation further aggravates cellular injury by the formation of reactive oxygen species (ROS), heat shock proteins and Damage Associated Molecular Patterns (DAMP). The latter in particular are implicated in the activation of the innate immune system and a non-specific inflammatory response including the release of inflammatory cytokines<sup>44</sup>. I sought to characterize this response in the auto-transplant setting by evaluating levels of circulating biomarkers of cell death and inflammation using the swine gracilis model.

In these studies, I chose to measure the following markers of ischemic cellular damage; creatine kinase (CK), aspartate transaminase (AST) and lactate dehydrogenase (LDH). In addition, I measured the markers of inflammation interleukin 6 (IL-6) and tumour necrosis factor-alpha (TNF- $\alpha$ ). CK, LDH and AST are well characterised markers of muscle damage, and as such were considered ideal for defining this effect in a muscle flap model<sup>45</sup>. TNF- $\alpha$  is an inflammatory cytokine produced by monocytes / macrophages during acute inflammation. It acts as a signalling molecule that can lead to cell apoptosis or necrosis<sup>46</sup>. IL-6 is a pro-inflammatory cytokine produced at the site of acute inflammation that induces several acute phase proteins, including C-reactive protein, serum amyloid A and fibrinogen<sup>47</sup>. TNF- $\alpha$  and IL-6 are therefore sensitive, but not specific, markers of inflammation induced by IRI.

The studies performed showed characteristic increases in circulating levels of these biomarkers that define the IRI phenomenon. Interestingly, the markers of muscle necrosis (CK, LDH, AST) showed proportionally higher increases than the markers of inflammation (IL-6, TNF- $\alpha$ ) (see Appendices 4-6). The findings of significant elevations of these biomarkers, despite the transplants being clinically 'successful', demonstrates the suitability of measuring these factors. In the flap transplant experiments reported at Appendices 4, 5 and 6; where the flaps were ischemic for three hours, the transplanted flaps were successfully revascularized at the recipient sites with no appreciable necrosis. However, there was a

measurable change in levels of AST, CK and LDH. There was also an elevation in IL-6 and TNF- $\alpha$ , however this was less significant. These rises were significant up to two days post-transplant but had uniformly normalized by day seven.

The selection of these markers therefore enabled the measurement of subclinical tissue damage that, none-the-less, could be significant in the stimulation of the immune response. Furthermore, they could be used to measure the effectiveness of the interventions performed in my experiments. There are however limitations of this approach; resource implications limit the scope of testing to the above non-specific markers of cell death and inflammation. The measurement of more specific DAMPs, for example, would elicit more granular information. Indeed, in the time since this work was performed more sensitive markers of immune rejection phenomena have become available in our labs. These include the mixed lymphocyte reaction to show rates of proliferation of T-Cells in response to alloantigen presentation by the APC, and analysis of gene expression in transplanted tissues<sup>48,49</sup>.

### **3.3 C1-esterase inhibitor and ischemia reperfusion injury**

The complement system has a significant role in IRI. This has been shown both *in vitro* and *in vivo*, and therapies addressing this phenomenon to treat cardiac and cerebral infarctions have been evaluated, although none have reached routine clinical use. C1-esterase inhibitor (C1-inh) has been shown to act on the intrinsic and lectin pathways of the complement system and reduce vascular permeability and inflammation<sup>50,51</sup>. Complement inhibition with C1-inh inhibits local anaphylatoxin release (C3a and C5a) and neutrophil migration into the ischemic tissue<sup>52</sup>. Additionally, the protective effect of C1-inh on the microcirculation, leukocyte rolling and adhesion secondary to ischemia and reperfusion has been shown in the myocardium, brain, pancreas, liver and mesentery microcirculation<sup>53</sup>.

In my protocol, presented at Appendix 4, swine gracilis musculocutaneous flaps were treated by arterial infusion of C1-inh solution, prior to an ischemic interval of three hours, and compared to controls that were treated by standard of care cold storage. Following this ischemic interval flaps were replanted (autotransplanted) into the heterotopic position of the animal's neck. The markers of ischemic tissue damage and inflammation described above were monitored by blood samples performed at intervals following the procedure. The results

showed a statistically significant decrease in circulating levels of CK and AST at the one day, and one and two days, post-operative time-points, respectively.

### **3.4 Hydrogen Sulphide and ischemia reperfusion injury**

Hydrogen sulphide ( $H_2S$ ) is one of three endogenous gasotransmitters (along with nitrogen oxide and carbon monoxide), it has an incompletely understood mechanism of action. Despite being toxic in high doses when applied exogenously, endogenously it has a role in modulating vascular tone, direct ant-oxidant effects on tissues and effects on metalloproteins<sup>54,55</sup>. These mechanisms are theorised to be responsible for the protective effects demonstrated experimentally on tissues including the kidney, lung, brain, heart, and vasculature<sup>56</sup>. In addition to these local effects, systemic administration has been shown to induce a state of suspended animation in mice; mice exposed to 80 parts per million for six hours showed a 50% reduction in oxygen consumption, a 60% reduction in carbon dioxide output and a 90% reduction in their metabolic rate and reduction of core body temperature to 2°C above ambient temperature<sup>57</sup>. In the protocol published at Appendix 5 I applied  $H_2S$  via arterial infusion to swine gracilis flaps subjected to a three-hour ischemic interval and compared them to the controls treated by cold storage, in the same manner as the C1-inh protocol. The hydrogen sulphide exhibited a more profound effect than the C1-inh, including showing a greater impact on the expression of markers of inflammation IL-6 and TNF- $\alpha$ ; hence this was translated to the allotransplant model (See Appendix 7)<sup>58</sup>.

### **3.5 *Ex vivo* tissue preservation and stabilisation**

The international solid organ transplant community has extensively studied *ex vivo* perfusion of transplantable tissues, to the extent that devices to preserve livers, kidneys, lungs, and hearts have been evaluated. Despite this interest, and the benefits this could deliver, none has yet reached routine clinical application<sup>59-63</sup>. Preserving organs in this manner could enable distant procurement and thus expand the donor pool, as well as streamline the logistics of transplant surgical centres and improve capacity. This has particular applicability in the VCA setting, as matching of grafts is even more rigorous than for solid organs; VCA grafts must be additionally matched for colour and size. Furthermore, they are more susceptible to IRI due to muscle components of the composite grafts, and donor rates of VCA grafts are lower

than for solid organs. These considerations have meant that most VCA centres use a single institution for both retrieval and implantation, hence the ability to extend the safe ischemia time of transplant grafts is highly desired

In addition to preserving tissues, *ex vivo* perfusion offers other possibilities, including the ability to modulate the tissue that is being preserved. This may include strategies that have an immunomodulatory effect such as de-cellularisation, or the implantation of drugs or stem cells.

By extrapolating work initially performed in the 1960s on whole animals, we used a proprietary hyperbaric perfusion chamber with an integrated oxygenation circuit to preserve the gracilis free flaps of the swine. This work is presented in Appendix 6<sup>64</sup>. In these experiments it was possible to demonstrate an equivalent level of tissue damage due to IRI despite a longer period of storage, and at a warmer temperature compared to traditional cold storage. Room temperature storage has great potential to reduce the logistical burden of graft transport.

This finding was translated into the analogous allotransplantation model to establish the effect on rates of immunologic rejection. In this experiment flaps maintained by the HBO device for a five-hour period were shown to have significantly delayed onset of acute rejection compared to flaps treated by three hours of standard of care cold storage.

The decision to reduce the ischemic interval for the control flaps compared to the intervention flaps was taken due to findings in the model development phase, acknowledging that this would present a challenge to our study design. Model development work had shown universal flap loss at cold ischemia periods of five hours, with no re-flow phenomenon and early necrosis being observed. However, flaps maintained on the HBO device for five hours, at 21°C, achieved satisfactory revascularization and long-term integration into the recipient site. The decision was therefore made that, to enable a comparison of outcomes, the control arm of the experiment would use a three-hour ischemic interval, while the intervention group would use a five-hour interval. The finding of equivalent levels of ischemic and inflammatory injury per measured biomarkers was therefore considered to be a positive result. The further finding that acute rejection was also delayed in the allotransplant arm of the experiment was

considered additional evidence of a positive effect. Despite this, it is a limitation of this experiment that controls of equal time periods were not used. Balancing ethical concerns for animal use, resource allocation in highly expensive protocols and rigorous protocol design is highly challenging. This problem is further confounded by the fact that outcomes of such experiments cannot be predicted. However, we were certainly able to achieve proof of concept and add to the body of work supporting targeted delivery of IRI ameliorating agents, ex vivo perfusion of tissue composites and the relationship between IRI and acute rejection.

These experiments thus achieved proof of concept that targeted drug delivery and ex vivo perfusion, in this case by direct vascular infusion, to the transplanted tissue composites could deliver significant results with respect to reduced muscle damage within the graft. Furthermore, this effect could be demonstrated at a systemic level by biochemical analysis of peripheral blood samples drawn remotely from the transplanted tissues that showed reduced levels of muscle damage and inflammation. Finally, the results were significantly robust to enable the direction of future research efforts; in this case translating these findings from the autotransplantation model to the allotransplantation model. Limitations of these studies include the use of historical controls, the relatively small number of subjects and the lack of mechanistical information, as well as the limited number of biomarkers used and their lack of specificity. However, in the context of large animal pre-clinical research and balancing resource availability with pragmatic study design these results are instructive and deliver against the aims of the protocols. The resulting papers (Appendices 4-6) have been cited 26 times in the peer reviewed literature.

## Chapter 4 – Ischemia Reperfusion Injury, Targeted Immunosuppression and Allotransplantation

### 4.1 Introduction

The culmination of my work was the translation of the findings of reduced rates of ischemia reperfusion injury (IRI) in autotransplantation into the allotransplantation models (gracilis musculocutaneous flap and orthotopic forelimb transplant) to evaluate the relationship between IRI and acute rejection (AR).

### 4.2 *Ex vivo* perfusion, ischemia reperfusion injury and acute rejection following delayed replantation

The hyperbaric oxygen *ex vivo* perfusion device described above was next used for allotransplantation. The flaps were transplanted to another, immunologically typed, recipient with standardized immunologic differences (equivalent to a single swine leukocyte antigen (SLA) difference. This enabled the evaluation of the contribution of IRI to AR. It was found that flaps perfused with oxygenated University of Wisconsin solution at three atmospheres of pressure for five hours showed reduced rates of IRI and correspondingly delayed onset of acute rejection compared to flaps that had been stored on ice in the standard manner for three hours.

Similarly the finding of reduced IRI in gracilis flaps that had been treated with arterial infusion of hydrogen sulphide ( $H_2S$ ) was translated to the allotransplantation model. In this protocol (Appendix 7) flaps were procured and subjected to three hours of cold ischemia before being allotransplanted into an immunologically typed recipient's neck. Intervention flaps were treated by arterial infusion of  $H_2S$  in the same manner as in the autotransplant protocol (Appendix 5). In this protocol it was possible to randomise flaps to treatment or control arms as flaps were procured from donor animals sequentially on the same day. The results of this protocol showed a delay in the onset of AR that was apparent both clinically and histopathologically. It was possible to blind the pathologist to the treatment arm of the specimens, however due to logistical constraints and the requirement of the research team



to perform the animal sedation and biopsy collection it was not possible to blind the clinical evaluation of rejection.

#### **4.3 Use of a hydrogel delivery system to delay the onset of acute rejection**

Finally, we evaluated the ability of a graft-implanted, enzyme-responsive, tacrolimus-eluting hydrogel platform to delay the onset of AR, utilizing the newly developed orthotopic forelimb model. Tacrolimus (TAC), a calcineurin inhibitor, is the mainstay of current 'triple therapy' immunosuppression regimens, along with prednisolone and mycophenolate mofetil (MMF)<sup>65</sup>. All three agents have effects on T-lymphocytes; TAC inhibits Interleukin 2 mediated activation of T lymphocytes, MMF sequesters T and B lymphocytes and prednisolone, in common with other corticosteroids, sequesters T lymphocytes. TAC is also used for targeted delivery in a topical preparation and considered most suitable for intra-graft delivery. The triglycerol monostearate hydrogel was developed by collaborators at Harvard University and was shown to deliver the drug in response to matrix metalloproteinase enzymes that are expressed in the presence of inflammation, such as found in AR<sup>66</sup>. The gels were loaded into the limb transplant graft in the sub-dermal layer on completion of the operation. Rejection-free survival of the limb was significantly prolonged by this technique.

Initial dosing levels were based on extrapolation from small animal data and were found to be toxic to the swine as they developed tacrolimus-induced pancreatitis<sup>67</sup>. Reduction of the dose however enabled extended graft survival with no clinically manifested adverse effects. Blood levels of tacrolimus were found to be negligible within three weeks of transplantation, despite limbs not being rejected for at least eight weeks. This was in contrast to control limbs that were universally rejected within seven days (see Appendix 8)<sup>68</sup>.

These experiments were highly resource intensive, with longer surgical periods, and in several cases up to three-month survival periods. I was able to perform eight gracilis transplants per week, however due to the surgical time and the increased husbandry requirements it was not possible to perform more than three forelimb transplants per week. Given the rejection of the two control limbs after six days it was considered unethical to perform further control experiments and subject animals to inevitable early rejection. However, this did reduce the statistical power of the experiment. Whilst it was possible to blind the histopathologist, again

it was not possible to blind or randomize the surgical team. A larger investigating team may have made this possible, however.

I was thus able to show that the same treatments that had reduced IRI in the autotransplant model used in the allotransplant configuration were able to delay significantly the onset of AR; confirming the link between IRI and AR, and suggesting strategies to ameliorate this effect. Furthermore, not only was targeted drug delivery via the intravascular route effective but also subcutaneous placement of drug eluting hydrogels was effective in delaying rejection, and the utility of the novel forelimb model that I had designed was confirmed. The papers published from these protocols have been cited 16 times in the peer reviewed literature.

## Chapter 5 – Conclusion and Future Direction

This thesis summarises a series of studies representing a six-year research journey into improving the outcomes of reconstructive transplantation. This is a coherent body of work; however, each study is a stand-alone example of hypothesis-based research, reflected by individual publication. To date these publications have been cited 49 times in the peer reviewed literature.

The current state of the art of vascularized composite allotransplantation (VCA), and the pre-clinical models used to deliver translational research outputs, were evaluated. This foundation was used to support the development of a new criterion-standard translatable model. This in turn was used to evaluate the over-arching hypothesis that targeted, graft specific, immunomodulatory therapies offer the potential to delay rejection of VCA grafts, whilst minimising systemic toxicity. Under this umbrella four strategies to target VCA grafts specifically, using C1-esterase infusion, hydrogen sulphide infusion, hyperbaric oxygen ex vivo perfusion and tacrolimus eluting hydrogels have been evaluated. The former three treatments were all shown to reduce the ischemia reperfusion injury of tissue transplantation. Of these, hydrogen sulphide infusion and hyperbaric ex vivo perfusion were translated into an allotransplantation model and were shown to delay the onset of acute rejection. These findings add further weight to the link between ischemia reperfusion injury and acute rejection. Finally, and most significantly, the direct application of tacrolimus to the transplanted graft using a hydrogel delivery system was shown to have the most pronounced effect on acute rejection of all the areas studied. This is particularly exciting as both tacrolimus and the hydrogel are licensed for clinical use. Thus, there is scope to apply this to clinical practice in the short to medium term.

This work has been extended by this group and others. In my current role as Division Chief of the Division of Plastic Surgery at the University of Texas Health, San Antonio, I am continuing to extend the envelope of survivability of flaps and investigating alternative perfusate solutions, including blood and synthetic oxygen carrier molecules, and alternative preservation devices. The forelimb model is still being used by the United States Army Institute of Surgical Research, also with respect to tissue preservation and ex vivo perfusion.

In Taiwan I evaluated the effects of the tacrolimus eluting hydrogel on nerve regeneration using a model of rat facial nerve injury at Chang Gung Memorial Hospital. Finally, in Oxford, I was a member of the Oxford Research in Plastic Surgery and Hand surgery Innovation Collaboration (ORPHIC) who are continuing to use ex vivo perfusion techniques to achieve not only tissue preservation but also modulation, including implanting pancreatic islet cells into fasciocutaneous flaps to potentially create a functional pancreatic transplant.

In conclusion, I have shown that targeted therapies directed at transplant grafts are both feasible and effective in the treatment of acute immunologic rejection. Translation of these findings into clinical practice has the potential to expand the application of vascularized composite allotransplantation. Continued iterative improvements in immunologic strategies will expand the indications for the field of reconstructive transplantation still further, whilst ex vivo perfusion, enabling not only extended tissue stabilization periods, but also tissue modulation, has vast potential to improve outcomes for patients who have suffered devastating tissue loss.

## References

1. Shores JT, Brandacher G, Lee WPA. Hand and upper extremity transplantation: an update of outcomes in the worldwide experience. *Plastic and reconstructive surgery*. 2015;135(2):351e-360e. doi:10.1097/prs.0000000000000892
2. Kumnig M, Jowsey-Gregoire SG. Key psychosocial challenges in vascularized composite allotransplantation. *World journal of transplantation*. 2016;6(1):91-102. doi:10.5500/wjt.v6.i1.91
3. Kaufman CL, Breidenbach W. World experience after more than a decade of clinical hand transplantation: update from the Louisville hand transplant program. *Hand clinics*. 2011;27(4):417-21-vii-viii. doi:10.1016/j.hcl.2011.08.004
4. Komatsu S, 43 STRS, 1968. *Successful Replantation of a Completely Cut-off Thumb; Case Report Plast.*; n.d. doi:10.1016/j.jhsa.2006.02.020
5. Fernandez JJG, Febres-Cordero RG, Simpson RL. The Untold Story of the First Hand Transplant: Dedicated to the Memory of one of the Great Minds of the Ecuadorian Medical Community and the World. *Journal of reconstructive microsurgery*. 2019;35(3):163-167. doi:10.1055/s-0038-1668535
6. Dubernard J, Owen E, Lefrançois N, et al. First human hand transplantation. *Transplant Int*. 2010;13(S1):S521-S524. doi:10.1111/j.1432-2277.2000.tb02095.x
7. Bertrand AA, Sen S, Otake LR, Lee GK. Changing attitudes toward hand allotransplantation among North American hand surgeons. *Annals of plastic surgery*. 2014;72 Suppl 1:S56-60. doi:10.1097/sap.0000000000000147
8. Alolabi N, Chuback J, Grad S, Thoma A. The utility of hand transplantation in hand amputee patients. *The Journal of hand surgery*. 2015;40(1):8-14. doi:10.1016/j.jhsa.2014.08.048
9. Petruzzo P, Lanzetta M, Dubernard JM, et al. The International Registry on Hand and Composite Tissue Transplantation. 2010;90(12):1590-1594. doi:10.1097/tp.0b013e3181ff1472
10. Carty MJ, Zuker R, Cavadas P, Pribaz JJ, Talbot SG, Pomahac B. The case for lower extremity allotransplantation. *Plastic and reconstructive surgery*. 2013;131(6):1272-1277. doi:10.1097/prs.0b013e31828bd1a5
11. Siemionow M. The decade of face transplant outcomes. *Journal of materials science Materials in medicine*. 2017;28(5):64. doi:10.1007/s10856-017-5873-z

12. Honeyman C, Fries CA. Vascularised Composite Allotransplantation – Basic Science and Clinical Applications. *International Journal of Orthoplastic Surgery*. 2019;2(1):13-22. doi:10.29337/ijops.28
13. Breidenbach WC, Meister EA, Becker GW, et al. A Statistical Comparative Assessment of Face and Hand Transplantation Outcomes to Determine Whether Either Meets the Standard of Care Threshold. *Plastic and reconstructive surgery*. 2016;137(1):214e-222e. doi:10.1097/prs.0000000000001893
14. Fries CA, Stark HL, Tudor D, Gorantla VS, Davis MR, Rickard RF. Upper limb reconstructive transplantation in military recipients: summary of world experience. *journal of royal naval medical service*. 2018;104(1):6-11. <https://mail.google.com/mail/u/0/>
15. Allin BSR, Ceresa CDL, Issa F, et al. A single center experience of abdominal wall graft rejection after combined intestinal and abdominal wall transplantation. *American journal of transplantation : official journal of the American Society of Transplantation and the American Society of Transplant Surgeons*. 2013;13(8):2211-2215. doi:10.1111/ajt.12337
16. Honeyman C, Dolan R, Stark H, et al. Abdominal Wall Transplantation: Indications and Outcomes. *Current Transplantation Reports*. 2020;361(9376):1-12. doi:10.1007/s40472-020-00308-9
17. Zamfirescu DG, Owen E, Lascar I, et al. Sentinel skin allograft-a reliable marker for monitoring of composite tissue transplant rejection. *Transplantation proceedings*. 2009;41(2):503-508. doi:10.1016/j.transproceed.2009.01.023
18. Gerlach UA, Vrakas G, Sawitzki B, et al. Abdominal Wall Transplantation: Skin as a Sentinel Marker for Rejection. *American journal of transplantation : official journal of the American Society of Transplantation and the American Society of Transplant Surgeons*. 2016;16(6):1892-1900. doi:10.1111/ajt.13693
19. Ali JM, Catarino P, Dunning J, Giele H, Vrakas G, Parmar J. Could Sentinel Skin Transplants Have Some Utility in Solid Organ Transplantation? *Transplantation proceedings*. 2016;48(8):2565-2570. doi:10.1016/j.transproceed.2016.06.040
20. Redett RJ, Etra JW, Brandacher G, et al. Total Penis, Scrotum, and Lower Abdominal Wall Transplantation. *The New England journal of medicine*. 2019;381(19):1876-1878. doi:10.1056/nejmc1907956
21. Selber JC, Chang EI, Clemens MW, et al. Simultaneous Scalp, Skull, Kidney, and Pancreas Transplant from a Single Donor. *Plastic and reconstructive surgery*. 2016;137(6):1851-1861. doi:10.1097/prs.0000000000002153
22. Momeni A, Chang B, Levin LS. Technology and vascularized composite allotransplantation (VCA)-lessons learned from the first bilateral pediatric hand transplant. *Journal of materials science Materials in medicine*. 2016;27(11):161. doi:10.1007/s10856-016-5771-9

23. Siemionow M, Gharb BB, Rampazzo A. Successes and lessons learned after more than a decade of upper extremity and face transplantation. *Current opinion in organ transplantation*. 2013;18(6):633-639. doi:10.1097/mot.0000000000000021
24. Leonard DA, Kurtz JM, Mallard C, et al. Vascularized composite allograft tolerance across MHC barriers in a large animal model. *American journal of transplantation : official journal of the American Society of Transplantation and the American Society of Transplant Surgeons*. 2014;14(2):343-355. doi:10.1111/ajt.12560
25. Klimczak A, Siemionow M. Immune responses in transplantation: application to composite tissue allograft. *Seminars in plastic surgery*. 2007;21(4):226-233. doi:10.1055/s-2007-991192
26. Madani H, Hettiaratchy S, Clarke A, Butler PEM. Immunosuppression in an emerging field of plastic reconstructive surgery: composite tissue allotransplantation. *Journal of plastic, reconstructive & aesthetic surgery : JPRAS*. 2008;61(3):245-249. doi:10.1016/j.bjps.2007.10.048
27. Shaheen MF, Shaheen FAM, Attar B, Elamin K, Hayyan HA, Sayyari AA. Impact of recipient and donor nonimmunologic factors on the outcome of deceased donor kidney transplantation. *Transplantation proceedings*. 2010;42(1):273-276. doi:10.1016/j.transproceed.2009.12.052
28. Kaufman CL, Ouseph R, Marvin MR, Manon-Matos Y, Blair B, Kutz JE. Monitoring and long-term outcomes in vascularized composite allotransplantation. *Current opinion in organ transplantation*. 2013;18(6):652-658. doi:10.1097/mot.0000000000000025
29. Lanzetta M, Petruzzo P, Dubernard JM, et al. Second report (1998-2006) of the International Registry of Hand and Composite Tissue Transplantation. *Transplant immunology*. 2007;18(1):1-6. doi:10.1016/j.trim.2007.03.002
30. Lantieri L, Cholley B, Lemogne C, Lancet RGT, 2020. First human facial retransplantation: 30-month follow-up. *Elsevier*. Published online n.d. doi:10.1016/s0140-6736(20)32438-7
31. Mundinger GS, Drachenberg CB. Chronic rejection in vascularized composite allografts. *Current opinion in organ transplantation*. 2014;19(3):309-314. doi:10.1097/mot.0000000000000073
32. Petruzzo P, Gazarian A, Kanitakis J, et al. Outcomes after bilateral hand allotransplantation: a risk/benefit ratio analysis. *Annals of surgery*. 2015;261(1):213-220. doi:10.1097/sla.0000000000000627
33. Petruzzo P, Sardu C, Lanzetta M, Dubernard JM. Report (2017) of the International Registry on Hand and Composite Tissue Allotransplantation (IRHCTT). *Current Transplantation Reports*. 2017;4(4):294-303. doi:10.1007/s40472-017-0168-3

34. Brandacher G, Lee WPA, Schneeberger S. Minimizing immunosuppression in hand transplantation. *Expert review of clinical immunology*. 2012;8(7):673-83-quiz 684. doi:10.1586/eci.12.54
35. Caterson EJ, Lopez J, Medina M, Pomahac B, Tullius SG. Ischemia-reperfusion injury in vascularized composite allotransplantation. *The Journal of craniofacial surgery*. 2013;24(1):51-56. doi:10.1097/scs.0b013e31827104e1
36. Amin KR, Wong JKF, Fildes JE. Strategies to Reduce Ischemia Reperfusion Injury in Vascularized Composite Allotransplantation of the Limb. *The Journal of hand surgery*. Published online October 18, 2017. doi:10.1016/j.jhsa.2017.09.013
37. Salminger S, Sturma A, Roche AD, et al. Functional and Psychosocial Outcomes of Hand Transplantation Compared with Prosthetic Fitting in Below-Elbow Amputees: A Multicenter Cohort Study. *PloS one*. 2016;11(9):e0162507. doi:10.1371/journal.pone.0162507
38. Brandacher G, Grahammer J, Sucher R, Lee W-PA. Animal models for basic and translational research in reconstructive transplantation. *Birth defects research Part C, Embryo today : reviews*. 2012;96(1):39-50. doi:10.1002/bdrc.21002
39. Fries CA, Tudor DW, Davis MR. Preclinical Models in Vascularized Composite Allotransplantation. *Current Transplantation Reports*. Published online June 28, 2015:1-8. doi:10.1007/s40472-015-0071-8
40. Barone AAL, Leonard DA, Torabi R, et al. The gracilis myocutaneous free flap in swine: an advantageous preclinical model for vascularized composite allograft transplantation research. *Microsurgery*. 2013;33(1):51-55. doi:10.1002/micr.21997
41. Villamaria CY, Rasmussen TE, Spencer JR, Patel S, Davis MR. Microvascular porcine model for the optimization of vascularized composite tissue transplantation. *The Journal of surgical research*. 2012;178(1):452-459. doi:10.1016/j.jss.2012.03.051
42. Fries CA, Villamaria CY, Spencer JR, Rickard RF, Gorantla VS, Davis MR. A Porcine Orthotopic Forelimb Vascularized Composite Allotransplantation Model. *Plastic and reconstructive surgery*. 2016;138(3):461e-471e. doi:10.1097/prs.0000000000002451
43. Wang WZ, Baynosa RC, Zamboni WA. Update on Ischemia-Reperfusion Injury for the Plastic Surgeon. *Plastic and reconstructive surgery*. 2011;128(6):685e-692e. doi:10.1097/prs.0b013e318230c57b
44. Messner F, Grahammer J, Hautz T, Brandacher G, Schneeberger S. Ischemia/reperfusion injury in vascularized tissue allotransplantation: tissue damage and clinical relevance. *Current opinion in organ transplantation*. 2016;21(5):503-509. doi:10.1097/mot.0000000000000343
45. Brancaccio P, Lippi G, Maffulli N. Biochemical markers of muscular damage. *Clin Chem Lab Med*. 2010;48(6):757-767. doi:10.1515/cclm.2010.179



46. Idriss HT, Naismith JH. TNF $\alpha$  and the TNF receptor superfamily: Structure-function relationship(s). *Microsc Res Techniq*. 2000;50(3):184-195. doi:10.1002/1097-0029(20000801)50:3<184::aid-jemt2>3.0.co;2-h
47. Tanaka T, Narazaki M, Kishimoto T. IL-6 in Inflammation, Immunity, and Disease. *Csh Perspect Biol*. 2014;6(10):a016295. doi:10.1101/cshperspect.a016295
48. DeWolf S, Shen Y, Sykes M. A New Window into the Human Alloresponse. *Transplantation*. 2016;100(8):1639-1649. doi:10.1097/tp.0000000000001064
49. Toulza F, Dominy K, Cook T, et al. Technical considerations when designing a gene expression panel for renal transplant diagnosis. *Sci Rep-uk*. 2020;10(1):17909. doi:10.1038/s41598-020-74794-3
50. Gorsuch WB, Chrysanthou E, Schwaeble WJ, Stahl GL. The complement system in ischemia-reperfusion injuries. *Immunobiology*. 2012;217(11):1026-1033. doi:10.1016/j.imbio.2012.07.024
51. Davis AE, Mejia P, Lu F. Biological activities of C1 inhibitor. *Molecular immunology*. 2008;45(16):4057-4063. doi:10.1016/j.molimm.2008.06.028
52. Caliezi C, Wuillemin WA, Zeerleder S, Redondo M, Eisele B, Hack CE. C1-Esterase inhibitor: an anti-inflammatory agent and its potential use in the treatment of diseases other than hereditary angioedema. *Pharmacol Rev*. 2000;52(1):91-112.
53. Horstick G. C1-esterase inhibitor in ischemia and reperfusion. *Immunobiology*. 2002;205(4-5):552-562. doi:10.1078/0171-2985-00154
54. Shefa U, Kim M-S, Jeong NY, Jung J. Antioxidant and Cell-Signaling Functions of Hydrogen Sulfide in the Central Nervous System. *Oxid Med Cell Longev*. 2018;2018:1-17. doi:10.1155/2018/1873962
55. Lv B, Chen S, Tang C, Jin H, Du J, Huang Y. Hydrogen Sulfide and Vascular Regulation- An Update. *J Adv Res*. 2020;27:85-97. doi:10.1016/j.jare.2020.05.007
56. Henderson PW, Weinstein AL, Sung J, Singh SP, Nagineni V, Spector JA. Hydrogen sulfide attenuates ischemia-reperfusion injury in in vitro and in vivo models of intestine free tissue transfer. *Plastic and reconstructive surgery*. 2010;125(6):1670-1678. doi:10.1097/prs.0b013e3181d4fdc5
57. Blackstone E, Morrison M, Roth MB. H<sub>2</sub>S induces a suspended animation-like state in mice. *Science (New York, NY)*. 2005;308(5721):518. doi:10.1126/science.1108581
58. Fries CA, Lawson SD, Wang LC, et al. Composite Graft Pretreatment With Hydrogen Sulfide Delays the Onset of Acute Rejection. *Annals of plastic surgery*. Published online January 9, 2019. doi:10.1097/sap.0000000000001693

59. Ardehali A, Esmailian F, Deng M, et al. Ex-vivo perfusion of donor hearts for human heart transplantation (PROCEED II): a prospective, open-label, multicentre, randomised non-inferiority trial. *Lancet*. Published online April 14, 2015. doi:10.1016/s0140-6736(15)60261-6
60. Bathini V, McGregor T, McAlister VC, Luke PPW, Sener A. Renal perfusion pump vs cold storage for donation after cardiac death kidneys: a systematic review. *The Journal of urology*. 2013;189(6):2214-2220. doi:10.1016/j.juro.2012.11.173
61. Brasile L, Glowacki P, Castracane J, Stubenitsky BM. Pretransplant kidney-specific treatment to eliminate the need for systemic immunosuppression. *Transplantation*. 2010;90(12):1294-1298. doi:10.1097/tp.0b013e3181ffba97
62. Yuan X, Theruvath AJ, Ge X, et al. Machine perfusion or cold storage in organ transplantation: indication, mechanisms, and future perspectives. *Transplant international : official journal of the European Society for Organ Transplantation*. 2010;23(6):561-570. doi:10.1111/j.1432-2277.2009.01047.x
63. Hart NA 't, Plaats A van der, Leuvenink HGD, et al. Hypothermic machine perfusion of the liver and the critical balance between perfusion pressures and endothelial injury. *Transplantation proceedings*. 2005;37(1):332-334. doi:10.1016/j.transproceed.2004.12.090
64. Fries CA, Villamaria CY, of JSJ, 2018. A Hyperbaric Warm Perfusion System Preserves Tissue Composites Ex vivo and Delays the Onset of Acute Rejection. *thieme-connect.com*. Published online n.d. doi:10.1055/s-0038-1667298
65. Morelon E, Kanitakis J, Petruzzo P. Immunological issues in clinical composite tissue allotransplantation: where do we stand today? 2012;93(9):855-859. doi:10.1097/tp.0b013e31824728b8
66. Vemula PK, Cruikshank GA, Karp JM, John G. Self-assembled prodrugs: an enzymatically triggered drug-delivery platform. *Biomaterials*. 2009;30(3):383-393. doi:10.1016/j.biomaterials.2008.09.045
67. Gajanayake T, Olariu R, Leclère FM, et al. A single localized dose of enzyme-responsive hydrogel improves long-term survival of a vascularized composite allograft. *Science translational medicine*. 2014;6(249):249ra110-249ra110. doi:10.1126/scitranslmed.3008778
68. Fries CA, Rickard RF, Davis MR, gorantla von s. Graft-Implanted, Enzyme Responsive, Tacrolimus-Eluting Hydrogel Enables Long- Term Survival of Orthotopic Porcine Limb Vascularized Composite Allografts: a Proof of Concept Study. *PloS one*. Published online October 29, 2018:1-44.

## Appendix 1 - Institutional Animal Care and Use Committee Training Courses

The IACUCs of the 59th Medical Development Wing Clinical Research Division, United States Air Force, and Tri-Service Research Laboratory, San Antonio, Texas, oversaw this training, respectively.

### CITI Collaborative Institutional Training Initiative

#### Human Research Curriculum

Basic Course Passed 19 Sep 2012 (Ref # 8732077)

Provider - University of Miami, Office of Research Education

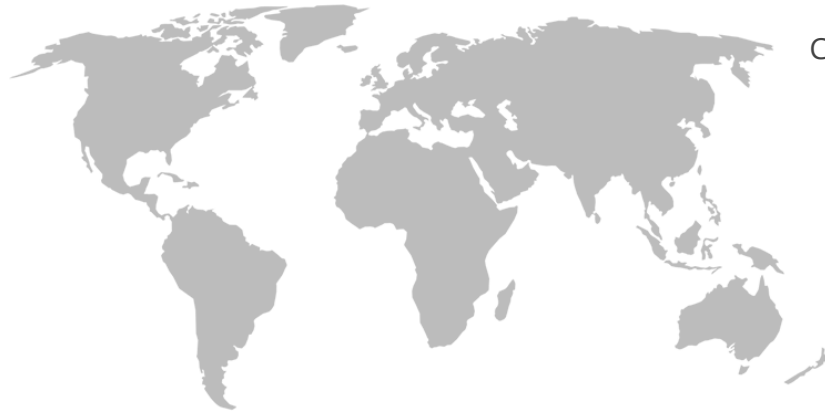Required Modules	Date completed	Result
Introduction	13/9/12	NA
History and Ethical Principles	17/9/12	5/6 (83%)
Basic Institutional Review Board (IRB) Regulations and Review Process	17/9/12	5/5 (100%)
Informed Consent	18/9/12	4/4 (100%)
Social and Behavioural Research for Biomedical Researchers	18/9/12	3/4 (75%)
Records-Based Research	18/9/12	1/2 (50%)
Genetic Research in Human Populations	18/9/12	2/2 (100%)
Research With Protected Populations - Vulnerable Subjects: An Overview	19/9/12	4/4 (100%)
Vulnerable Subjects - Research Involving Children	19/9/12	2/3 (67%)
Vulnerable Subjects - Research Involving Pregnant Women, Human Fetuses, and Neonates	19/9/12	3/3 (100%)

FDA-Regulated Research	19/9/12	5/5 (100%)
Research and HIPAA Research Protections	19/9/12	4/5 (80%)
Conflicts of Interest in Research Involving Human Subjects	19/9/12	5/5 (100%)
Wilford Hall Medical Center	19/9/12	3/3 (100%)

### Animal Care and Use Courses

Provider - American Association for Laboratory Animal Science

Course Title	Date completed	Result
<b>Assistant Laboratory Animal Technician</b> Swine (2009)	19/9/12	80%
<b>Anesthesia and Analgesia</b> Pain Recognition and Alleviation in Laboratory Animals	19/9/12	80%
<b>Ethical Decision-Making in Animal Research Courses</b> Ethical Decision-Making in Animal Research	19/9/12	80%
<b>Laboratory Animal Technologist</b> Occupational Health and Safety (2007)	19/9/12	80%
<b>US Mandates and Guidelines</b> Public Health Service Policy on Humane Care and Use of Laboratory Animals	19/9/12	90%



Completion Date 19-Sep-2012  
Expiration Date 19-Sep-2015  
Record ID 8732077

This is to certify that:

**Charles Fries**

Has completed the following CITI Program course:

Not valid for renewal of certification  
through CME.

**Human Research**  
(Curriculum Group)  
**Group 1. BIOMEDICAL RESEARCH**  
(Course Learner Group)  
**1 - Basic Course**  
(Stage)

Under requirements set by:

**U.S. Air Force - Wilford Hall Ambulatory Surgical Center**

**CITI**  
Collaborative Institutional Training Initiative

Verify at [www.citiprogram.org/verify/?wdd1e8efd-d266-40ae-850f-8cd7bb6ebf89-8732077](http://www.citiprogram.org/verify/?wdd1e8efd-d266-40ae-850f-8cd7bb6ebf89-8732077)





## Appendix 2



# *Preclinical Models in Vascularized Composite Allotransplantation*

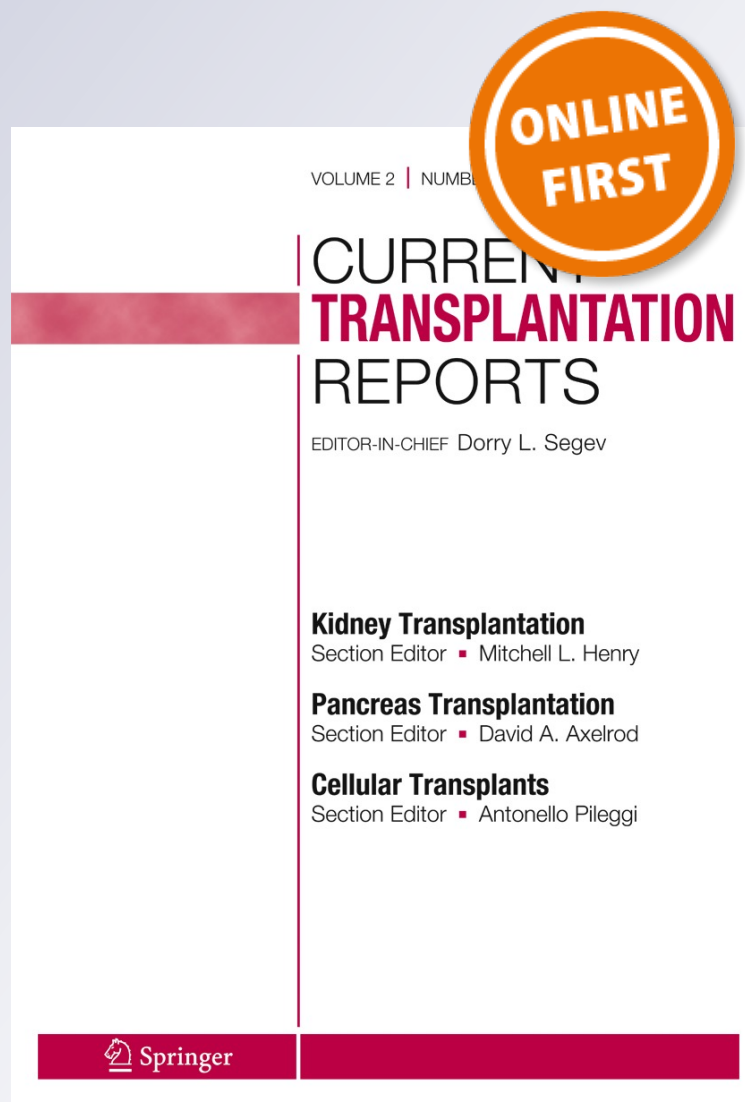
**C. Anton Fries, Dmitry W. Tuder & Michael R. Davis**

**Current Transplantation Reports**

e-ISSN 2196-3029

Curr Transpl Rep

DOI 10.1007/s40472-015-0071-8



















## Appendix 3

























## Appendix 4















## Appendix 5













## Appendix 6

























## Appendix 7

















## Appendix 8


RESEARCH ARTICLE

# Graft-implanted, enzyme responsive, tacrolimus-eluting hydrogel enables long-term survival of orthotopic porcine limb vascularized composite allografts: A proof of concept study

C. Anton Fries<sup>1,2\*</sup>, Shari D. Lawson<sup>1</sup>, Lin C. Wang<sup>1</sup>, Kai V. Slaughter<sup>3</sup>, Praveen K. Vemula<sup>4</sup>, Ashish Dhayani<sup>4,5</sup>, Nitin Joshi<sup>3,6</sup>, Jeffrey M. Karp<sup>3,6</sup>, Rory F. Rickard<sup>2</sup>, Vijay S. Gorantla<sup>7,8</sup>, Michael R. Davis<sup>1,8</sup>

**1** United States Army Institute of Surgical Research, San Antonio, TX, United States of America, **2** Royal Centre for Defence Medicine, ICT Centre, Birmingham, United Kingdom, **3** Center for Nanomedicine and Division of Engineering in Medicine, Department of Medicine, Brigham and Women's Hospital, Boston, MA, United States of America, **4** Institute for Stem Cell Biology and Regenerative Medicine (inStem), UAS-GKVK Campus, Bangalore, India, **5** The School of Chemical and Biotechnology, SASTRA University, Thanjavur, India, **6** Harvard Medical School, Boston, MA, United States of America, **7** Wake Forest Institute for Regenerative Medicine, Wake Forest University School of Medicine, Winston Salem, NC, United States of America, **8** RESTOR Program, 59th MDW/ Science and Technology, Joint Base San Antonio, TX, United States of America

\* [antonfries@gmail.com](mailto:antonfries@gmail.com)



## OPEN ACCESS

**Citation:** Fries CA, Lawson SD, Wang LC, Slaughter KV, Vemula PK, Dhayani A, et al. (2019) Graft-implanted, enzyme responsive, tacrolimus-eluting hydrogel enables long-term survival of orthotopic porcine limb vascularized composite allografts: A proof of concept study. PLoS ONE 14 (1): e0210914. <https://doi.org/10.1371/journal.pone.0210914>

**Editor:** Stanislaw Stepkowski, University of Toledo, UNITED STATES

**Received:** November 18, 2018

**Accepted:** January 3, 2019

**Published:** January 24, 2019

**Copyright:** This is an open access article, free of all copyright, and may be freely reproduced, distributed, transmitted, modified, built upon, or otherwise used by anyone for any lawful purpose. The work is made available under the [Creative Commons CC0](https://creativecommons.org/licenses/by/4.0/) public domain dedication.

**Data Availability Statement:** All relevant data are within the manuscript and its Supporting Information files.

**Funding:** The studies were supported by intramural grant funding from the US Air Force Medical Service Agency (59MDW Office of Science and Technology) and in part by extramural funding from Department of Defense Grant W81XWH-15-2-0047 Log MR141085 (Reconstructive Transplant

## Abstract

### Background

Currently, patients receiving vascularized composite allotransplantation (VCA) grafts must take long-term systemic immunosuppressive therapy to prevent immunologic rejection. The morbidity and mortality associated with these medications is the single greatest barrier to more patients being able to receive these life-enhancing transplants. In contrast to solid organs, VCA, exemplified by hand or face transplants, allow visual diagnosis of clinical acute rejection (AR), directed biopsy and targeted graft therapies. Local immunosuppression in VCA could reduce systemic drug exposure and limit adverse effects. This proof of concept study evaluated, in a large animal forelimb VCA model, the efficacy and tolerability of a novel graft-implanted enzyme-responsive, tacrolimus (TAC)—eluting hydrogel platform, in achieving long-term graft survival.

### Methods

Orthotopic forelimb VCA were performed in single haplotype mismatched mini-swine. Controls (n = 2) received no treatment. Two groups received TAC hydrogel: high dose (n = 4, 91 mg TAC) and low dose (n = 4, 49 mg TAC). The goal was to find a dose that was tolerable and resulted in long-term graft survival. Limbs were evaluated for clinical and histopathological signs of AR. TAC levels were measured in serial blood and skin tissue samples. Tolerability of the dose was evaluated by monitoring animal feeding behavior and weight.

Research Program). CAF was funded by a fellowship from the United Kingdom Ministry of Defence. J.M.K. and N.J. were financially supported by Department of Defense (DOD) award W81XWH-14-1-0229, a Disease Targeted Innovative Research Grant from Rheumatology Research Foundation, a grant from King Abdulaziz City for Science and Technology through the Center of Excellence for Biomedicine (CEBM) and with the support of the Football Players Health Study at Harvard. The Football Players Health Study is funded by a grant from the National Football League Players Association. The content is solely the responsibility of the authors and does not necessarily represent the official views of Harvard Medical School, Harvard University or its affiliated academic health care centers, the National Football League Players Association, or the Brigham and Women's Hospital.

**Competing interests:** J.M.K. and P.K.V. hold equity in Alivio Therapeutics, a company that has an option to license IP generated by J.M.K. and P.K.V., and that may benefit financially if the IP is licensed and further validated. The interests of J.M.K. was reviewed and is subject to a management plan overseen by his institution in accordance with its conflict of interest policies. N.J. and K.V.S. have generated IP that has been licensed to Alivio Therapeutics. Other authors declare no conflicts of interest. This does not alter the authors' adherence to PLOS ONE policies on sharing data and materials.

## Results

Control limbs underwent Banff Grade IV AR by post-operative day six. Low dose TAC hydrogel treatment resulted in long-term graft survival time to onset of Grade IV AR ranging from 56 days to 93 days. High dose TAC hydrogel also resulted in long-term graft survival (24 to 42 days), but was not well tolerated.

## Conclusion

Graft-implanted TAC-loaded hydrogel delays the onset of Grade IV AR of mismatched porcine forelimb VCA grafts, resulting in long term graft survival and demonstrates dose-dependent tolerability.

## Introduction

The life-changing reconstructive benefits and routine clinical utilization of VCA have been hampered by the risks related to lifelong, high-dose, multi-drug immunosuppression [1]. To date, uncontrolled acute rejection (AR) or chronic rejection (CR) has led to numerous graft losses [2,3]. Medication non-compliance is also a major contributor to preventable graft failure [4]. Tacrolimus (TAC), the mainstay drug in VCA, has a very narrow therapeutic range, with variable diurnal peaks and troughs after oral delivery [5]. Unlike solid organs, VCA offers unique opportunities for visual graft surveillance for clinical rejection as well as access to directed biopsies and graft targeted drug delivery [3,6,7].

Agents like TAC can be encapsulated in self-assembled hydrogels to create “enzyme-responsive depots”, that can be customized for on-cue spatiotemporal release in VCA tissues [8–10]. Our program has developed an injectable, enzyme-responsive delivery platform that provides on-cue release of TAC in VCA tissues in the presence of matrix metalloproteinases (MMPs), or other proteases in the extracellular milieu produced by graft infiltrating macrophages. MMPs (esp. MMP2 and MMP9) are critical mediators in AR and CR (vasculopathy) in solid organs. Suppressing early MMP (or other protease) driven immune events may be graft protective in VCA [6].

Prior work by team members in rodent limb VCA established the efficacy of the platform. A single-dose of TAC-laden hydrogel (7 mg TAC in 1 ml triglycerol monostearate [TGMS] gel), injected subcutaneously, allowed rejection-free limb transplant survival for more than 100 days with no additional systemic immunosuppression [10]. They have also demonstrated the utility of this platform in other diseases associated with over expression of MMPs and other enzymes [11,12]. This proof of concept study was designed to determine the tolerability and efficacy of the TAC delivery platform in a stringent, pre-clinical large animal (porcine), mismatched, orthotopic forelimb VCA model [13]. Specifically, we evaluated the tolerability and efficacy of two different doses of TAC-loaded TGMS hydrogel in porcine VCA. The goal was to identify a TAC dose that is tolerable and results in long-term graft survival. Given the relatively narrow therapeutic window for TAC, two doses that were close—49 mg and 93 mg—were investigated. VCA graft survival and episodes of acute rejection were evaluated. Tolerability of TAC hydrogel was determined by monitoring animal feeding behavior and weight.

## Methods

All experiments were performed at the Tri-Service Research Laboratories, United States Army Institute for Surgical Research, Fort Sam Houston, San Antonio, Texas. These were in



accordance with a protocol independently reviewed and approved by the Institutional Animal Care and Use Committee (IACUC) of the Tri-Service Research Laboratory.

## Animals

Single haplotype mismatched Yucatan mini-pigs (*Sus scrofa domestica*) (Sinclair Bio Resources LLC, Columbia, MO), served as donors and recipients for VCA procedures. All animals were housed and maintained in accordance with IACUC guidelines. Procedures were in compliance with American Association for the Accreditation of Laboratory Animal Care (AALAC) recommendations and the principles set forth in the National Institute of Health Publication, 'Guide for the Care and Use of Laboratory Animals' and the Animal Welfare Act of 1966, as amended. Humane endpoints were used in this study to determine time of euthanasia, out-with the protocol endpoints of grade IV limb rejection, or reaching the end of the protocol duration (100 days); otherwise euthanasia was performed on reaching these protocol end-points. Animal death was not an endpoint of the study. Euthanasia was by means of intravenous Sodium-Pentobarbital, 100mg/kg, via ear vein. Animals were reviewed daily by the veterinary technicians and research team and as required by the staff veterinarian of the TSRL. The analgesic regimen required was Buprenorphine SR (ZooPharm, Windsor, CO) 0.15mg/kg every 72 hours and ketoprofen (Fort Dodge animal health, New York, NY) 3mg/kg immediately post-operatively and then on an as required basis at the discretion of the attending veterinarian. All research team members had completed the American Association for Animal Laboratory Sciences training courses in Pain Recognition and Alleviation in Laboratory Animals and Euthanasia of Research Animals: AVMA Guidelines. In total 10 animals were utilized in this protocol of which none were found dead, two were euthanized prior to study end points. In both of these cases this was due to failure to thrive of the animals manifest by loss of body weight. In all cases euthanasia was performed immediately animals had reached study endpoints.

## Orthotopic porcine forelimb transplantation

This protocol utilized an orthotopic, fully weight-bearing porcine forelimb VCA model that was developed by our group and previously published [13]. Salient procedural details are summarized as follows:

Anesthesia was induced and maintained by isoflurane following premedication with intramuscular ketamine. Subjects were positioned supine with the left forelimb in abduction. Two teams operated simultaneously to prepare donor and recipient. The left forelimb was dissected at its mid-point via a "fish-mouth" skin incision. The neurovascular bundle, containing the brachial artery and associated vena comitantes and median nerve was exposed, ligated and divided. Due attention was given to adequacy of length of the neurovascular pedicle and tendons in order to achieve a tension free neuro-vascular repair and physiological tendon balancing following transplantation. An osteotomy was performed at the midpoint of the radio-ulna on the donor and recipient and rigid fixation was accomplished with two weight bearing six-hole 3mm plates and tri-cortical locking screws. All neurovascular structures were microsurgically coapted and tendon repairs performed using standard techniques. The skin was closed without tension and leg splinted in a plaster cast anchored by a single Steinmann pin to prevent slippage of the cast (Fig 1).

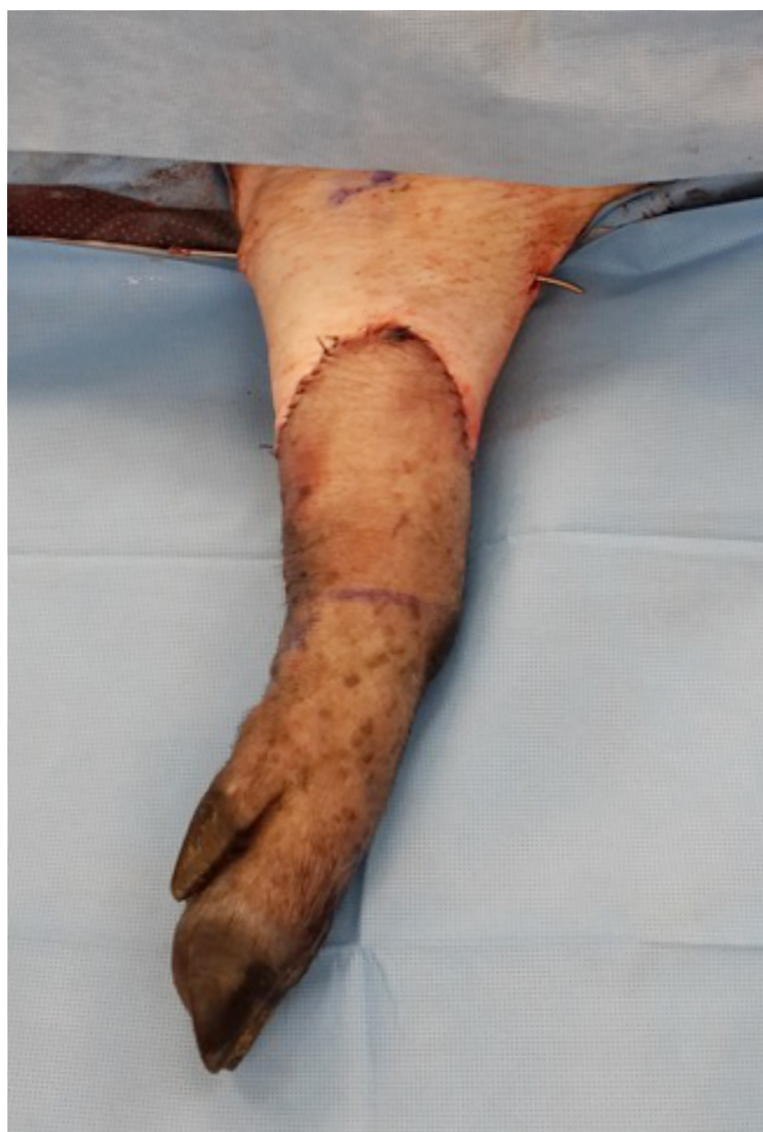## Immunological mismatch

Donor and recipient pairs were selected across a standardized immunologic mismatch [14]. For clinical relevance, a mismatch was sought equivalent to an un-related deceased donor (one

HLA mismatch). Four distinctive porcine leukocyte antigen (SLA) haplotypes, locally designated as “w”, “x”, “y” and “z”, were characterized in the Yucatan miniature pigs breeds [14]. A crossover haplotype, designated “q”, consisting class I of “w” and class II of “z”, was also detected in the breed. The SLA genotype of the Yucatan pigs used in this study was verified at three class I (SLA-1, -2, -3) and three class II (DRB1, DQB1 and DQA) genes using the low-resolution (Lr) PCR-SSP (sequence-specific primer) typing assays as described [15].

### Groups and interventions

Three animal groups were investigated in the study. Group 1 (Controls,  $n = 2$ ), received no treatment. Group 2 (Experimental group,  $n = 4$ ) received high dose TAC hydrogel, 91mg, per limb. Group 3 (Experimental group,  $n = 4$ ) received low dose TAC hydrogel, 49 mg, per limb. Doses were estimated based on extrapolations on a per-weight basis using allometric calculations from prior published rat hind limb studies [10].



**Fig 1. Orthotopic forelimb allotransplantation.** Transplant recipients can mobilize immediately after recovery in a surgical cast that is fixed with a single Steinmann pin.

<https://doi.org/10.1371/journal.pone.0210914.g001>

## Preparation of TAC hydrogels

TAC eluting, self-assembled, amphiphilic triglycerol monostearate (TGMS) hydrogels were prepared by Dr Karp's laboratory at Brigham and Women's hospital, Boston, MA [9]. Encapsulation of TAC to form TGMS-TAC hydrogels was achieved by heating TGMS (10%w/v) and 7 mg of TAC in DMSO/water (1:4 v/v) in a glass scintillation vial to 60–80°C until dissolution resulting in TAC concentrations of 7 mg/ml. The vial was allowed to cool until gelation had occurred. The resultant hydrogel containing 7 mg/ml TAC was loaded in individual 1 ml syringes. These were stored in refrigerated conditions (4°C) until used and allowed to reach room temperature prior to injection.

## Administration of TAC hydrogel and dosing protocol

Immediately prior to skin closure the TGMS-TAC hydrogel was injected through a 19-G needle into the loose connective tissue in the sub-dermal plane of the forelimb VCA. Animals received TAC hydrogels in two dosing regimens: high dose (Group 2, n = 4, 91 mg TAC) and low dose (Group 3, n = 4, 49 mg TAC). Each injection was in the form of a 1ml aliquot containing 7mg of TAC. The limb was divided into identically sized quadrants, each of which received the total dose in 1ml single split-dose injections. The goal was to achieve a uniform distribution of drug in the VCA tissues. The skin was then closed using interrupted 3–0 vicryl sutures to the dermal layer and 4–0 nylon to the skin.

## Clinical and histopathologic assessment of rejection

Grafts were monitored daily for signs of acute rejection and histopathologically by skin biopsy on post-operative days one, four, seven and then weekly thereafter until the end point of study (the development Banff Grade IV rejection). The primary clinical and histopathologic diagnosis of rejection was based on previously described Banff Classification of VCA [16–18]. Clinically grafts were monitored for a consistent progression of rejection from erythema, macule formation, blistering, desquamation of the epidermis and finally frank necrosis. Animals were sedated with intramuscular 4–6mg/kg Telazol (tiletamine hydrochloride and zolazepam hydrochloride combination, Zoetis, Parsippany, NJ). The casts were removed and limbs examined and photographed. Two representative 4 mm punch skin biopsies were taken from limb areas most affected clinically by rejection and frozen in liquid nitrogen (for tissue TAC levels) or fixed in 10% buffered formalin and paraffin embedded. All were stained with hematoxylin-eosin (H&E; Fischer Scientific, Fair Lawn, NJ) after rehydration with serial xylene, ethyl alcohol, and deuterated water rinses. Slides were evaluated by an independent, blinded, veterinary pathologist with transplant experience. The staff veterinarian at the TSRL performed necropsies on all subjects following euthanasia once study end-points had been reached to further evaluate evidence of drug toxicity.

## Assessment of TAC levels in whole blood and skin of VCA

Auricular vein blood sampling was performed regularly (every 3–4 days for the first two weeks followed by every 6–10 days after till end point). Whole blood levels of TAC, were analyzed using liquid chromatography mass spectroscopy (LC–MS/MS). Forelimb skin biopsies were collected simultaneously with blood samples for tissue TAC level measurement. Skin biopsies of the VCA were homogenized and TAC extracted with methanol. The methanolic solution was evaporated and residue was reconstituted with blood/plasma and analyzed by LC–MS/MS. Blood and tissue drug levels were calculated and expressed as ng/ml or ng/ml of homogenate. Samples were vortex mixed for 30s with a mixture of methanol and ZnSO<sub>4</sub> (70:30, v/v).

Ascomycin was used as an internal standard for TAC. After centrifugation, the supernatant was put in an auto sampler for injection into the system. Drug was eluted on C18-reversed phase column (150 mm, 3.0 mm; 5 $\mu$ m) by a mixture of water and ammonium acetate solution (80:20 v/v). Intra-assay and inter-assay imprecisions were acceptable (<10%), and mean absolute recovery was 89%. This method was validated in the range of 2 – 40ng/ml for TAC with the lower limit of quantification (LLQ) set at 2ng/ml for TAC with an acceptable precision (CV<15%). Each sample was analyzed in three replicates [19].

## Data analysis

Pharmacokinetic profiles and parameters were evaluated using Graph pad prism 6 and Win-nonlin 6. Systemic exposure ( $C_{max}$ ) and local tissue concentrations were measured after drug encapsulated hydrogel administered directly into the graft. For statistical analysis, mean defect areas and standard deviations were calculated and compared among groups by a 3 x 4 (group by time post-op), and two-way analysis of variance (ANOVA). Inter-group differences were assessed by Bonferroni multiple-comparison test (SPSS v12). Mean differences were considered significant if  $p < 0.05$ . In all experiments VCA survival between groups was compared by ANOVA or Turkey-Kramer post hoc test where appropriate. When only two comparisons could be made, an unpaired two-sided t-test was used. Continuous variables were expressed as mean  $\pm$  SEM. For the ANOVA outcomes, 80% power and 5% significance were used to find a 25% difference in outcomes. Survival analysis and differences in survival probabilities along with their standard errors were reported using log rank (Mantel-Cox) statistics.

## Results

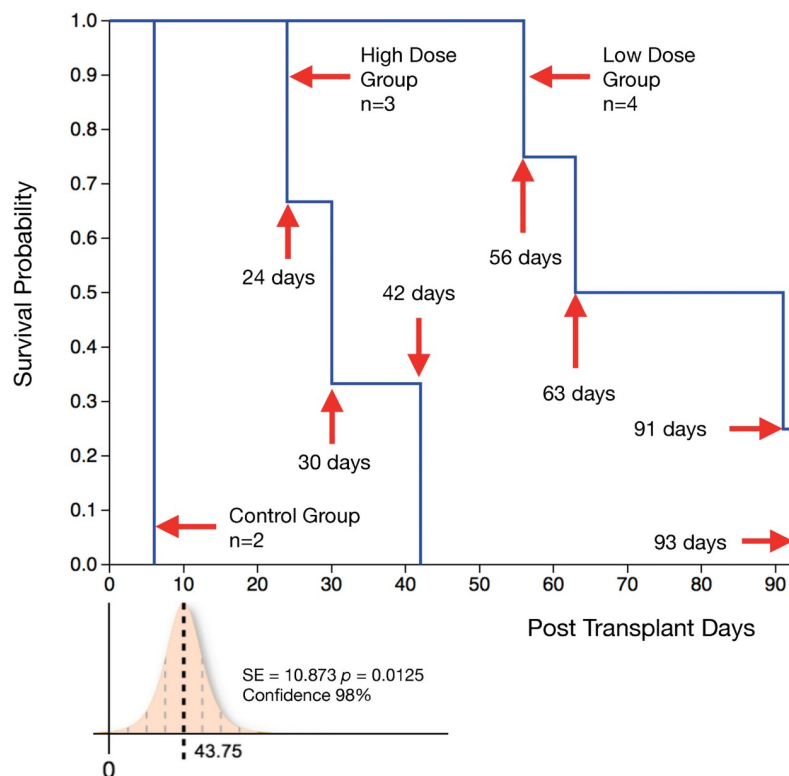
### High dose and low dose hydrogels prolong graft survival compared to controls

Untreated Group 1 controls ( $n = 2$ ) reached Grade IV AR at post-operative day (POD) 6 and 7 respectively. In Group 2 ( $n = 4$ ; high dose TAC hydrogel, 91mg per limb) one animal was excluded from study due to flap failure on POD 1. Three animals that were followed up for the study showed prolonged graft survival without onset of Grade IV rejection compared to controls. However, they failed to thrive with poor feeding and weight loss, requiring early euthanasia at varying time points (POD 24,30,42). Pancreatitis was demonstrated post-mortem in these animals. Group 3 animals ( $n = 4$ ; low dose TAC hydrogel, 49mg per limb) showed prolonged graft survival to onset of Grade IV rejection (POD 56,63,91,93). The survival difference between the high dose group (death censored) and low dose group was statistically significant ( $p = 0.0125$ ); the high dose animals required to be euthanized with non-rejecting grafts due to failure to thrive (Fig 2).

### Drug release from hydrogels coincides with graft immune events and macrophage activity

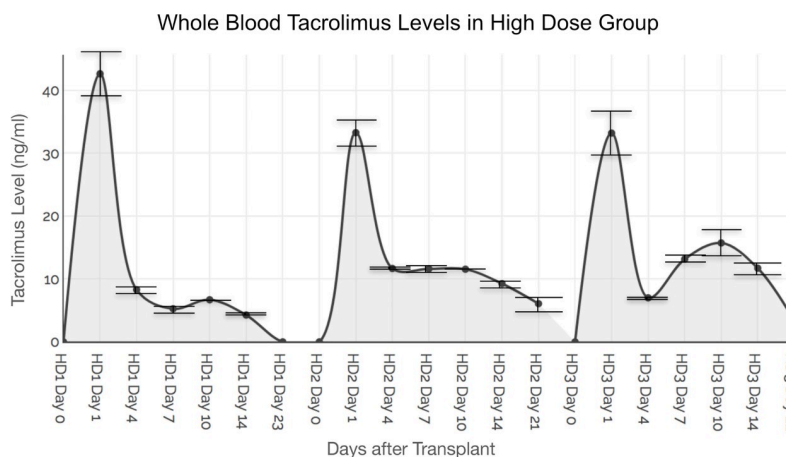
Whole blood TAC levels (averaged from triplicate samples, mean  $\pm$  SD) in the three Group 2 animals were: 42.6 ng/ml  $\pm$  2.73 ng/ml on POD 1 reducing to 4.27  $\pm$  0.14 ng/ml on POD 23; 33.35  $\pm$  4.74 ng/ml on POD 1 reducing to 6.08  $\pm$  0.22 ng/ml on POD 21; and 33.18  $\pm$  2.95 ng/ml on POD 1 reducing to 3.37  $\pm$  0.18 ng/ml on POD 22. Fig 3 shows whole blood levels and of systemic TAC values of triplicate samples at each time point.

The tissue TAC levels (in triplicate samples) in the skin in the three Group 2 animals were as follows: 1322.74  $\pm$  162.96 ng/ml on POD 1 reducing to 5.60  $\pm$  0.24 ng/ml on POD 14; 799.51  $\pm$  9.43 ng/ml on POD 1 reducing to 2.16  $\pm$  0.21 ng/ml on POD 14; and 945.88  $\pm$



**Fig 2. Kaplan-Meier survival plot of time to reaching Grade III rejection in transplanted limb.** The hazard rate for AR differs between the high dose and low dose group (log-rank test;  $z = 2.57$ ,  $p = 0.0101$ , Confidence—98%). There is a survival difference between high dose group (death censored) and low dose group ( $p = 0.0125$ ) (high dose animals required to be euthanized with non-rejecting grafts due to failure to thrive).

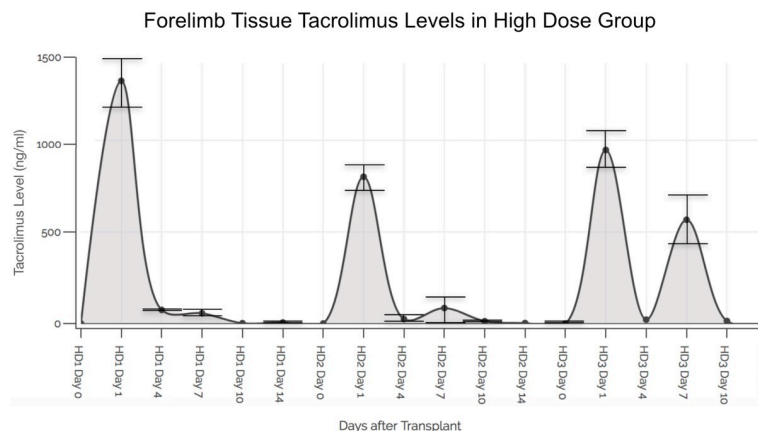
<https://doi.org/10.1371/journal.pone.0210914.g002>



**Fig 3. Whole blood tacrolimus levels in high dose group.** Animals receiving hydrogels containing 91 mg (total dose) of TAC demonstrated a burst release of TAC (ranging between 30 and 40 ng/ml) at POD 1 that coincided with macrophage activation secondary to inflammatory events from surgical trauma and ischemia-reperfusion injury. A secondary spike of TAC release was observed at around POD 10 in all animals that possibly coincides with onset of AR events in the VCA. Lower panel demonstrates mean TAC levels coinciding with macrophage-mediated graft immune events. Standard deviations (SD) of TAC levels in triplicate whole blood samples are shown.

<https://doi.org/10.1371/journal.pone.0210914.g003>



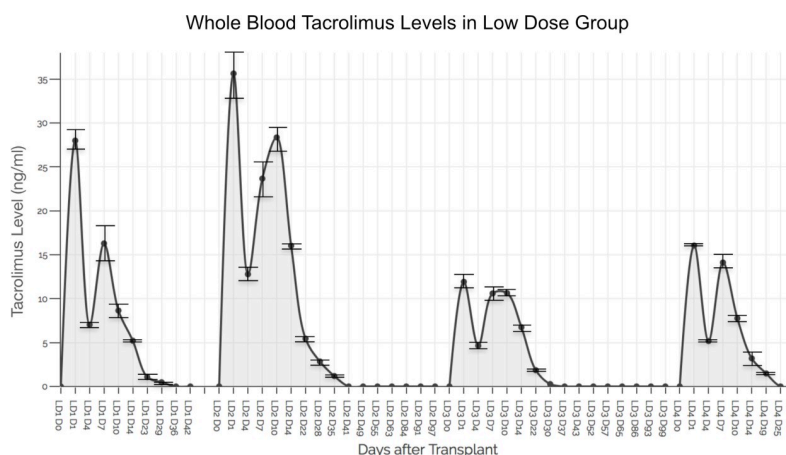


**Fig 4. Tacrolimus levels in forelimb VCA skin tissue in high dose group.** Animals receiving hydrogels containing 91 mg (total dose) of TAC demonstrated a burst release of TAC (ranging between 500 and 1500 ng/gm) in forelimb skin tissue at POD 1 that coincided with macrophage activation secondary to inflammatory events from surgical trauma and ischemia- reperfusion injury. A secondary spike of TAC release was observed at around POD 7 in all animals that possibly coincides with onset of AR events in the VCA. Mean TAC levels coinciding with macrophage-mediated graft immune events are shown. Standard deviations (SD) of TAC levels in triplicate tissue samples are shown.

<https://doi.org/10.1371/journal.pone.0210914.g004>

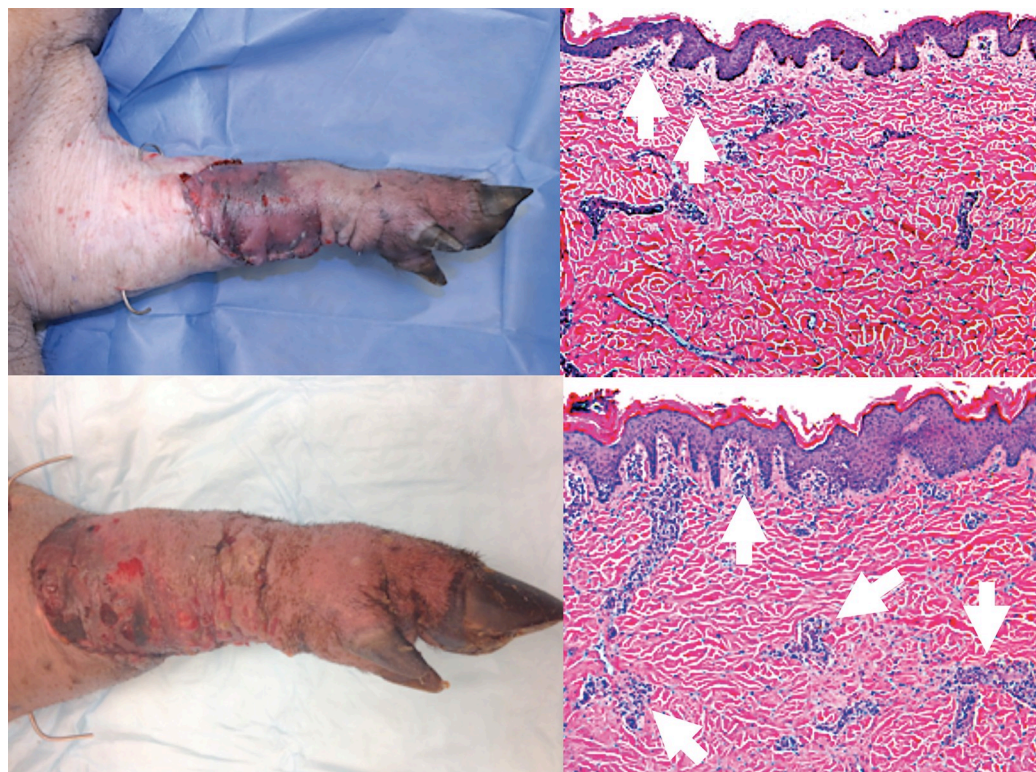
6.28 ng/ml on POD 1 reducing to 2.93  $\pm$  1.11 ng/ml on POD 14. The levels of TAC in the graft tissues versus the whole blood in the same animal at similar time points of analysis were significantly higher (ranging from 100 to 1000-fold,  $p > 0.001$  to  $p > 0.0001$ ) (Fig 4).

Whole blood TAC levels (in triplicate samples) in the four Group 3 animals were as follows: 27.98  $\pm$  1.48 ng/ml on POD 1 reducing to 0.48  $\pm$  0.15 ng/ml on POD 29 and to undetectable thereafter until end point POD 42; 35.62  $\pm$  1.19 ng/ml on POD 1 reducing to 1.19  $\pm$  0.15 ng/ml on POD 35 and to undetectable thereafter until end point POD 97; 11.91  $\pm$  0.5 ng/ml on POD 1 reducing to 0.27  $\pm$  0.25 ng/ml on POD 30 and to undetectable thereafter until end point POD 99; 16.05  $\pm$  0.77 ng/ml on POD 1 reducing to 1.48  $\pm$  0.24 ng/ml on POD 19 and to undetectable thereafter until end point POD 27 (Fig 5).



**Fig 5. Whole blood tacrolimus levels in low dose group.** Animals receiving hydrogels containing 49 mg (total dose) of TAC demonstrated a burst release of TAC (ranging between 10 and 35 ng/ml) at POD 1 that coincided with macrophage activation secondary to inflammatory events from surgical trauma and ischemia-reperfusion injury. A secondary spike of TAC release was observed between POD 7–10 in all animals that possibly coincides with onset of AR events in the VCA. Mean TAC levels coinciding with macrophage-mediated graft immune events are shown. Standard deviations (SD) of TAC levels in triplicate whole blood samples are shown.

<https://doi.org/10.1371/journal.pone.0210914.g005>



**Fig 6. Clinical and histopathologic assessment of rejection.** Top left panel: Banff Grade 1 AR (clinical picture) Top right panel: Histopathology of Grade 1 AR showing mild perivascular infiltration (arrows). No involvement of overlying epidermis. Bottom left panel: Banff Grade 2 AR (clinical picture) Bottom right panel: Histopathology of Grade 2 AR showing perivascular inflammation with/without mild epidermal or adnexal involvement (arrows). No epidermal dyskeratosis or apoptosis observed.

<https://doi.org/10.1371/journal.pone.0210914.g006>

An initial spike in TAC release was observed in Group 2 in whole blood samples on POD 1 after surgery (coincident with macrophage activity in surgical inflammation and reperfusion injury) [20]. Another spike was observed at POD 7 or 10 after surgery (coincident with macrophage activity in AR) (Fig 3) [21]. These findings are mirrored in the results of the tissue samples at the same time-points (Fig 4).

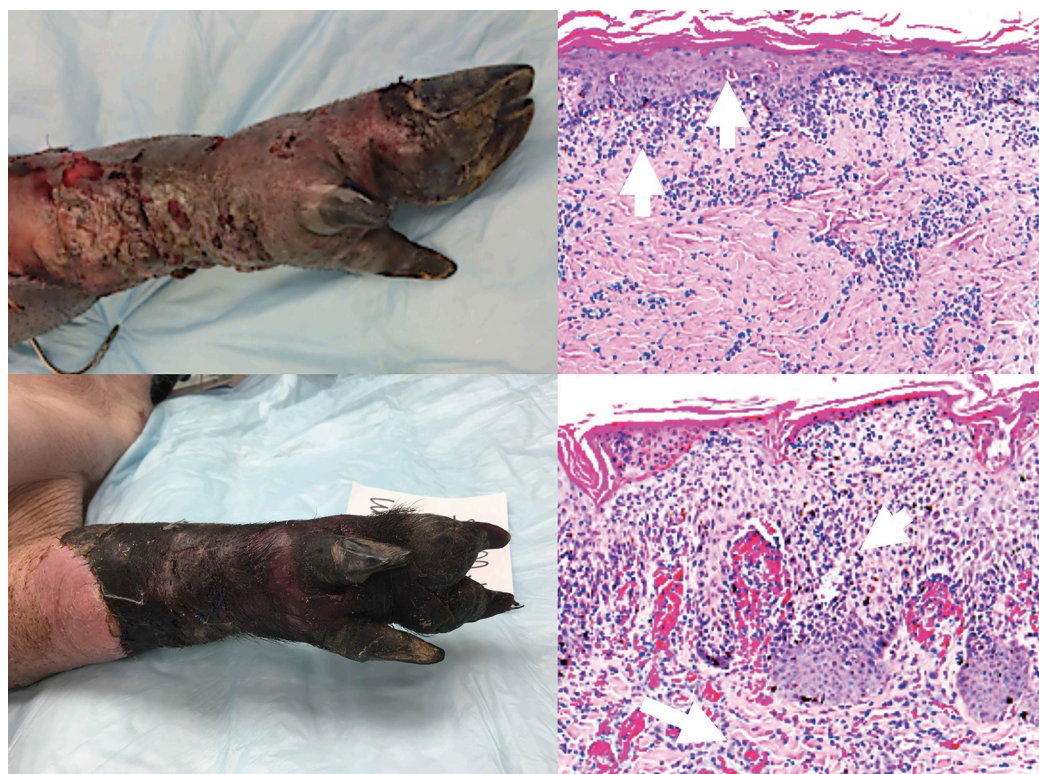
Consistent with findings in Group 2, Group 3 animals demonstrated an initial spike in TAC release in whole blood samples on POD 1 after surgery (coincident with macrophage activity in surgical inflammation and reperfusion injury) and at POD 7 or 10 after surgery (coincident with the timing of AR in control animals) (Fig 5).

Figs 6 and 7 show representative images of clinical and histopathological manifestations of rejection in this study. According to the Banff classification of skin containing composite tissue allografts manifestations of acute cell-mediated rejection includes immune cell infiltration of the skin (this may be neutrophils and / or lymphocytes) to the dermis and epidermal and / or adnexal involvement [17].

## Discussion

Despite evolving clinical experience and progress in the understanding of the biology of VCA, one of the main factors preventing wider acceptance and routine clinical application are the associated adverse effects of long-term immunosuppression [22]. Since most VCA are non-





**Fig 7. Clinical and histopathologic assessment of rejection.** Top left panel: Banff Grade 3 AR (clinical picture) Top right panel: Histopathology of Grade 3 AR showing dense inflammation and epidermal involvement with apoptosis, dyskeratosis, and/or keratinolysis (arrows). Bottom left panel: Banff Grade 4 AR (clinical picture) Bottom right panel: Histopathology of Grade 4 AR showing necrotizing acute rejection. Frank necrosis of epidermis and presence of microvascular thrombi in deep dermal capillaries.

<https://doi.org/10.1371/journal.pone.0210914.g007>

life-saving procedures, the risks and toxicity of immunosuppression must be carefully balanced against their potential life enhancing benefits [23].

TAC remains the mainstay in the majority of VCA drug regimens [5]. TAC is a calcineurin inhibitor with a very narrow therapeutic range (range of exposure between the therapeutic threshold and the toxic threshold). Furthermore its pharmacokinetics result in blood level fluctuation, or diurnal peaks and troughs and intra or inter-patient blood level variability after oral delivery. Variable intestinal absorption or skipped doses due to non-compliance may lead to recurrent under immunosuppression and increased risk of AR or CR [24]. Attempts to restore trough levels to the therapeutic range may result in over immunosuppression resulting in supra-threshold peaks with risks such as nephrotoxicity, malignancy and opportunistic infection [25]. Consistent and reliable maintenance of patients within a therapeutic range is thus extremely challenging. Finally TAC blood levels do not proportionally correlate with graft tissue drug concentrations and there is significant inter-patient and intra-patient variability in drug exposure at comparable doses [7].

Oral administration of TAC in VCA is associated with extensive first-pass metabolism in the liver, greatly reducing its bioavailability due to actions of enzymes of the gastrointestinal lumen and lining, bacterial enzymes, and hepatic enzymes. Combined with possible renal clearance, only a small percentage of the drug typically reaches target graft tissues. The ratio of systemic versus local graft exposure is thus very high. Consequently, large and repeated dosing is often necessary.



Unlike solid organs, VCA tissues are accessible for visual monitoring and local intervention, such as topical therapies. It is thus possible to administer immunosuppressants locally to the graft, avoiding or minimizing systemic immunosuppression [3,7]. Recent innovation in bioengineering, nanotechnology, and regenerative medicine has enabled the development of a hydrogel system that can be embedded in transplanted grafts [26–28]. Such site-specific graft immunosuppression could facilitate long term graft survival while minimizing systemic immunosuppression and reducing the number of systemic drugs required [6,7]. TAC-loaded hydrogel can be injected subcutaneously or intramuscularly, to act as a drug depot that is enzyme responsive. The hydrogel can be disassembled by MMPs produced by macrophages including Langerhans cells and dermal dendritic cells to release TAC [29]. Such a system shows minimal drug release in normal physiological conditions but increased drug release when there is immune activity in the VCA tissues, resulting in prolonged efficacy of the gel. Most importantly, such graft embedded hydrogels may improve safety, efficacy, and patient compliance.

Our porcine model of orthotopic forelimb VCA provides the requisite stringency to investigate the efficacy of TAC-loaded TGMS hydrogel in a large animal model. Swine are relatively docile, economical and have very similar anatomy and tissue composition to humans, making them an optimal model for VCA. Also, the immune responses in this model are similar to those observed in humans [30].

In this proof of concept, exploratory study, a single dose of both low dose (49mg / forelimb graft) and high dose (91mg / forelimb graft) TAC hydrogels achieved long-term survival, ranging from 24 days to 93 days. The low dose was better tolerated than the high dose, which resulted in weight loss and poor feeding, in these cases pancreatitis was diagnosed post-mortem. Notably, these results were achieved in the absence of any systemic immunosuppression or antibody induction as in the clinical scenario. This is the first time such long-term VCA survival has been demonstrated in a pre-clinical large animal model with a graft implanted TAC delivery platform.

Limitations of the study that merit further elucidation in future work are acknowledged. Animal numbers were chosen with adherence to the principle of ‘reduction’ of live subjects to that which would enable demonstration of proof of concept. Additional groups, including controls with standard systemic immunosuppression (tacrolimus, mycophenolate mofetil +/- corticosteroids), for example would have added power to the protocol. Attempts at using linear regression models for correlating Banff grades of AR with graft survival in animals were constrained by the low animal numbers. This type of information can be extremely valuable as this drug delivery platform is developed for clinical application.

Repeated biopsies in the VCA graft could have triggered iatrogenic inflammation with macrophage trafficking and activation. We thus did not rely on immunohistochemical evaluation of macrophage specific markers (such as CD68) on biopsy samples as macrophage infiltration could occur due to the biopsy-induced inflammation. Rather, an assessment of T-cell infiltration and correlation of severity and location of lymphocytic infiltration with standardized grading systems such as the Banff Score of AR was performed. Whilst no animals developed signs of systemic sepsis the presence of a Steinman pin for retention of the cast in the initial phases may also have triggered some TAC release. These factors could have caused non-specific release of TAC, potentially leading to premature drug exhaustion in the gels with breakthrough AR and accelerated graft loss. The desire to perform more regular skin biopsies was tempered by this concern. The lack of a depletion induction regimen as used clinically sets a higher burden for success on the hydrogel drug delivery system [31–33]. Adjunctive systemic immune suppression was not included on this protocol to prevent confounding the effects of the graft embedded platform, however it is recognized that in clinical practice these will likely

be combined [34]. Although Group 2 animals receiving the higher dose TAC suffered from morbidity as compared to Group 3, the whole blood concentrations (Cmax of TAC) as well as time (in days) to baseline (standard error 3.536, confidence 99% and  $p = 0.0492$ ) were not significantly different between the two groups (Figs 2 and 3). A bioequivalence study of the two doses and the time points of testing during the follow was not performed, thus not allowing for an area under curve (AUC) determination with each dosing regimen. Future studies will focus on correlation of Cmax with the AUC to develop bioequivalence of dosing regimens. Cmax/AUC measurements could address intra-subject variations and pharmacokinetics of the gel platform in VCA.

It was found that increase in tissue levels and whole blood levels of TAC coincided in timing with inflammation associated with the surgical trauma or rejection responses as confirmed by biopsy. It is also possible that tissue levels of TAC could have varied based on the site of skin biopsy and subsequent inflammation. This is because of variables such as amount of drug released in the vicinity of the biopsy (macrophage activity secondary to trauma induced inflammation can fluctuate across the graft as AR can be heterogeneous) and differing fat content in the skin; TAC is lipophilic and porcine tissues have variable adipose tissue concentration depending on site [3, 35–37]. We were constrained in our analysis of macrophage migration and activation patterns due to the lack of availability of non-invasive cell tracking methods as well as in vivo cellular markers of macrophage activation in the porcine model. However, as the biopsies were taken at the site of most severe rejection, it is considered that higher levels of TAC here would be representative of the response. All these factors imply that the sensitivity and specificity of the TAC hydrogel delivery system as well as the measurement and monitoring methodology of graft delivered immunosuppression in VCA applications has to be optimized. An important goal is to restrict TAC release to the specific setting of AR and not in response to non-specific (such as infection) or iatrogenic inflammation (such as punch biopsy). Repeated dosing (every 20–30 days) may improve antirejection efficacy of this platform by improving bioavailability and bioactivity of TAC. These efforts are ongoing in our laboratories.

Taken together, an in-situ, graft implanted, immunosuppressive system as proposed holds promise towards long-term graft survival and improved patient quality of life in VCA. Allo-graft targeted immunosuppressive strategies therefore deserve further investigation to reduce risk and expand the broader clinical benefits of VCA.

## Supporting information

**S1 Table. High dose animals (Group 2) blood tacrolimus levels.**  
(XLSX)

**S2 Table. High dose animals tissue (Group 2) tacrolimus levels.**  
(XLSX)

**S3 Table. Low dose animals blood (Group 3) tacrolimus levels.**  
(XLSX)

**S4 Table. Rejection grade by time, all groups.**  
(XLSX)

## Acknowledgments

We thank the veterinarians and technicians at the Tri-Service Research Laboratory for excellent surgical support and post-operative animal care; in particular Ms Carrie Crane, Head,

Veterinary Science, Naval Medical Research Unit, San Antonio (NAMRU-SA), TX, Ms Candice Angueira, Program Manager, NAMRU-SA, TX, and LTC Craig Koeller, Attending Veterinarian, NAMRU-SA. We are also grateful to LTC Diedre Stoffregen, Veterinary Pathologist, NAMRU-SA, and Dr Wayne Kornegay, Veterinary Pathologist, NAMRU-SA. for histopathologic processing and evaluation; and Amber Nagy, Ph.D., Yoon Hwang, Ph.D., and Eric Botts, M.S., Department of Biomaterials Environmental Surveillance, Naval Medical Research Unit San Antonio, Fort Sam Houston for their help in TAC drug level monitoring.

## Author Contributions

**Conceptualization:** C. Anton Fries, Nitin Joshi, Jeffrey M. Karp, Rory F. Rickard, Vijay S. Gorantla, Michael R. Davis.

**Data curation:** C. Anton Fries, Shari D. Lawson, Lin C. Wang, Nitin Joshi, Vijay S. Gorantla, Michael R. Davis.

**Formal analysis:** C. Anton Fries, Shari D. Lawson, Lin C. Wang, Ashish Dhayani, Nitin Joshi, Jeffrey M. Karp, Rory F. Rickard, Vijay S. Gorantla, Michael R. Davis.

**Funding acquisition:** Nitin Joshi, Jeffrey M. Karp, Rory F. Rickard, Vijay S. Gorantla, Michael R. Davis.

**Investigation:** C. Anton Fries, Shari D. Lawson, Lin C. Wang, Praveen K. Vemula, Nitin Joshi, Jeffrey M. Karp, Vijay S. Gorantla, Michael R. Davis.

**Methodology:** C. Anton Fries, Kai V. Slaughter, Praveen K. Vemula, Nitin Joshi, Jeffrey M. Karp, Vijay S. Gorantla, Michael R. Davis.

**Project administration:** C. Anton Fries, Lin C. Wang, Kai V. Slaughter, Jeffrey M. Karp, Vijay S. Gorantla, Michael R. Davis.

**Resources:** Kai V. Slaughter, Praveen K. Vemula, Ashish Dhayani, Nitin Joshi, Jeffrey M. Karp, Rory F. Rickard, Vijay S. Gorantla, Michael R. Davis.

**Supervision:** Rory F. Rickard, Michael R. Davis.

**Validation:** Ashish Dhayani, Nitin Joshi.

**Writing – original draft:** C. Anton Fries, Vijay S. Gorantla, Michael R. Davis.

**Writing – review & editing:** C. Anton Fries, Shari D. Lawson, Lin C. Wang, Kai V. Slaughter, Praveen K. Vemula, Ashish Dhayani, Nitin Joshi, Jeffrey M. Karp, Rory F. Rickard, Vijay S. Gorantla, Michael R. Davis.

## References

1. Gorantla V, Maldonado C, Frank J, Barker J H. Composite Tissue Allotransplantation (CTA): Current Status and Future Insights. *Eur J Trauma*. 2001; 27(6):267–274.
2. Schneeberger S, Gorantla V S, Hautz T, Pulikkotti B, Margreiter R, Lee W P. Immunosuppression and Rejection in Human Hand Transplantation. *Transplant Proc*. 2009 Mar; 41(2):472–5.
3. Gorantla V S, Demetris A J. Acute and chronic rejection in upper extremity transplantation: what have we learned? *Hand Clin*. 2011 Nov; 27(4):481–93. <https://doi.org/10.1016/j.hcl.2011.08.006> PMID: 22051389
4. Fine R N, Becker Y, De Geest S, Eisen H, Ettenger R, Evans R, et al. Nonadherence consensus conference summary report. *Am J Transplant*. 2009 Jan; 9(1):35–41. <https://doi.org/10.1111/j.1600-6143.2008.02495.x> PMID: 19133930
5. Gorantla V S, Barker J H, Jones J W, Prabhune K, Maldonado C, Granger DK. Immunosuppressive agents in transplantation: mechanisms of action and current anti-rejection strategies. *Microsurgery* 2000; 20(8):420–9. PMID: 11150994

6. Gorantla V S, Plock J A, Davis M R. in *Anesthesia and Perioperative Care for Organ Transplantation* 539–552 (Springer New York, 2016). [https://doi.org/10.1007/978-1-4939-6377-5\\_44](https://doi.org/10.1007/978-1-4939-6377-5_44)
7. Schnider J T, Weinstock M, Plock J A, Solari M G, Venkataramanan R, Zheng X X et al. Site-specific immunosuppression in vascularized composite allotransplantation: prospects and potential. *Clin Dev Immunol*. 2013; 2013:495212. <https://doi.org/10.1155/2013/495212> PMID: 23476677
8. Vemula P K, Cruikshank G A, Karp J M, John G. Self-assembled prodrugs: An enzymatically triggered drug-delivery platform. *Biomaterials*. 2009 Jan; 30(3):383–93. <https://doi.org/10.1016/j.biomaterials.2008.09.045> PMID: 18930313
9. Vemula P K, Wiradharma N, Ankrum J A, Miranda O R, John G, Karp J M. Prodrugs as self-assembled hydrogels: a new paradigm for biomaterials. *Curr Opin Biotechnol*. 2013 Dec; 24(6):1174–82. <https://doi.org/10.1016/j.copbio.2013.02.006> PMID: 23465753
10. Gajanayake T, Olariu R, Leclerc F M, Dhayani A, Yang Z, Bongoni A K et al. A single localized dose of enzyme-responsive hydrogel improves long-term survival of a vascularized composite allograft. *Sci Transl Med*. 2014 Aug 13; 6(249):249ra110.
11. Zhang S, Ermann J, Succi M D, Zhou A, Hamilton M J, Cao B, et al. An inflammation-targeting hydrogel for local drug delivery in inflammatory bowel disease. *Sci Transl Med*. 2015 Aug 12; 7(300):300ra128. <https://doi.org/10.1126/scitranslmed.aaa5657> PMID: 26268315
12. Joshi N, Yan J, Levy S, Bhangchandani S, Slaughter K V, Sherman N E, et al. Towards an arthritis flare-responsive drug delivery system. *Nat Commun*. 2018 Apr 3; 9(1):1275. <https://doi.org/10.1038/s41467-018-03691-1> PMID: 29615615
13. Fries C A, Villamaria C Y, Spencer J R, Rickard R F, Gorantla V S, Davis M R. A Porcine Orthotopic Forelimb Vascularized Composite Allotransplantation Model. *Plast Reconstr Surg*. 2016 Sep; 138(3):461e–471e. <https://doi.org/10.1097/PRS.0000000000002451> PMID: 27556621
14. Ho C-S, Martens G W, Amoss M S Jr, Gomez-Raya L, Beattie C W, Smith D M. Swine leukocyte antigen (SLA) diversity in Sinclair and Hanford swine. *Dev Comp Immunol*. 2010 Mar; 34(3):250–7. <https://doi.org/10.1016/j.dci.2009.09.006> PMID: 19782700
15. Ho C-S, Lee J-H, Lunney J K, Franco-Romain M H, Smith D M. 6-OR: A comprehensive system for tissue-typing pigs. *Hum Immunol*. 2009 Nov; 70(1):S3
16. Cendales L C, Kanitakis J, Schneeberger S, Burns C, Ruiz P, Rimmelink M et al. The Banff 2007 working classification of skin-containing composite tissue allograft pathology. in 8, 1396–1400 (Wiley/Blackwell (10.1111), 2008).
17. Cendales L C, Kanitakis J, Schneeberger S, Burns C, Ruiz P, Rimmelink M et al. The Banff 2007 Working Classification Of Skin-Containing Composite Tissue Allograft Pathology. *Am J Transplant*. 2008 Jul; 8(7):1396–400. <https://doi.org/10.1111/j.1600-6143.2008.02243.x> PMID: 18444912
18. Pruett T L. The Banff 2007 Working Classification of Skin-Containing Composite Tissue Allograft Pathology. *Yearbook of Surgery* 2009, 109–110 (2009).
19. Kirresh T, Tuteja S, Russo D, Brophy P D, Murry D J. Development and validation of a liquid chromatography–mass spectrometric assay for simultaneous determination of tacrolimus and 13-O-desmethyl tacrolimus in rat kidney tissue. *J Pharm Biomed Anal*. 2017 Mar 20; 136:32–37. <https://doi.org/10.1016/j.jpba.2016.12.034> PMID: 28063333
20. Khalil A A, Aziz F A, Hall J C. Reperfusion injury. *Plast Reconstr Surg*. 2006 Mar; 117(3):1024–1033. <https://doi.org/10.1097/01.prs.0000204766.17127.54> PMID: 16525303
21. Messner F, Grahammer J, Hautz T, Brandacher G, Schneeberger S. Ischemia/reperfusion injury in vascularized composite allotransplantation: tissue damage and clinical relevance. *Curr Opin Transplant*. 2016 Oct; 21(5):503–509.
22. Gorantla V S, Breidenbach W C. *Transplantation of Composite Tissue Allografts* 215–233 (Springer US, 2008). [https://doi.org/10.1007/978-0-387-74682-1\\_16](https://doi.org/10.1007/978-0-387-74682-1_16)
23. Gorantla V S, Brandacher G, Schneeberger S, Zheng X X, Donnenberg A D, Losee J E, et al. Favoring the risk-benefit balance for upper extremity transplantation—the Pittsburgh Protocol. *Hand Clin*. 2011 Nov; 27(4):511–20. <https://doi.org/10.1016/j.hcl.2011.08.008> PMID: 22051391
24. Howsare M, Jones C M, Ramirez A M. Immunosuppression maintenance in vascularized composite allotransplantation: what is just right? *Curr Opin Organ Transplant*. 2017 Oct; 22(5):463–469. <https://doi.org/10.1097/MOT.0000000000000456> PMID: 28759463
25. Venkataramanan R, Swaminathan A, Prasad T, Jain A, Zuckerman S, Warty V et al. Clinical Pharmacokinetics of Tacrolimus. *Clin Pharmacokinet*. 1995 Dec; 29(6):404–430. <https://doi.org/10.2165/00003088-199529060-00003> PMID: 8787947
26. Rosenblum D, Joshi N, Tao W, Karp J M, Peer D. Progress and challenges towards targeted delivery of cancer therapeutics. *Nat Commun*. 2018 Apr; 9(1):1410. <https://doi.org/10.1038/s41467-018-03705-y> PMID: 29650952

27. Urello M A, Luo T, Fang B, Kiick K L, Sullivan M O. Drug and Gene Delivery for Regenerative Engineering. Reference Module in Biomedical Sciences (Elsevier, 2017). <https://doi.org/10.1016/B978-0-12-801238-3.99892-1>
28. Valeur E, Knerr L, Ölwegård-Halvarsson M, Lemurell M. Targeted delivery for regenerative medicines: an untapped opportunity for drug conjugates. *Drug Discov Today*. 2017 Jun; 22(6):841–847. <https://doi.org/10.1016/j.drudis.2016.12.004> PMID: 27988360
29. Spiller K L, Koh T J. Macrophage-based therapeutic strategies in regenerative medicine. *Adv Drug Deliv Rev*. 2017 Dec 1; 122:74–83. <https://doi.org/10.1016/j.addr.2017.05.010> PMID: 28526591
30. Fries C A, Tuder D W, Davis M R. Preclinical Models in Vascularized Composite Allotransplantation. *Curr Transplant Rep*. 2015 Sep; 2(3):284–289.
31. Weissenbacher A, Boesmueller C, Brandacher G, Oellinger R, Pratschke J, Schneeberger S. Alemtuzumab in solid organ transplantation and in composite tissue allotransplantation. *Immunotherapy*. 2010 Nov; 2(6):783–90. <https://doi.org/10.2217/imt.10.68> PMID: 21091110
32. LaMattina J C, Mezrich J D, Hofmann R M, Foley D P, D'Alessandro A M, Sollinger H W, et al. Alemtuzumab as compared to alternative contemporary induction regimens. *Transpl Int*. 2012 May; 25(5):518–26. <https://doi.org/10.1111/j.1432-2277.2012.01448.x> PMID: 22394259
33. Schneeberger S, Landin L, Kaufmann C, Gorantla V S, Brandacher G, Cavadas P et al. Alemtuzumab: key for minimization of maintenance immunosuppression in reconstructive transplantation? *Transplant Proc*. 2009 Mar; 41(2):499–502. <https://doi.org/10.1016/j.transproceed.2009.01.018> PMID: 19328912
34. Ana Luisa R P, Manuel Alejandro M F. in *Understanding the Complexities of Kidney Transplantation* (InTech, 2011). <https://doi.org/10.5772/17632>
35. Summerfield A, Meurens F, Ricklin M E. The immunology of the porcine skin and its value as a model for human skin. *Mol Immunol*. 2015 Jul; 66(1):14–21. <https://doi.org/10.1016/j.molimm.2014.10.023> PMID: 25466611
36. Monziols M, Bonneau M, Davenel A, Kouba M. Comparison of the lipid content and fatty acid composition of intermuscular and subcutaneous adipose tissues in pig carcasses. *Meat Sci*. 2007 May; 76(1):54–60. <https://doi.org/10.1016/j.meatsci.2006.10.013> PMID: 22064191
37. Barbero A M, Frasch H F. Pig and guinea pig skin as surrogates for human in vitro penetration studies: A quantitative review. *Toxicol In Vitro*. 2009 Feb; 23(1):1–13. <https://doi.org/10.1016/j.tiv.2008.10.008> PMID: 19013230

## Appendix 9



ALAMO  
ORTHOPEDICS™

10010 Rogers Crossing, Suite 308  
San Antonio, TX 78251  
(210) 598-5605; (210) 598-5620 fax

24 May 2021

Warwick University Board of Examiners  
Coventry CV4 7AL, United Kingdom

Re: Dr C A Fries contribution to publication

Dear Members of the Board,

Please accept this letter as confirmation that Dr. Anton Fries personally wrote and edited the manuscript titled "Preclinical Models in Vascularized Composite Allotransplantation" that was published in Current Transplantation Reports. Preclinical Models in Vascularized Composite Allotransplantation C A Fries, D W Tudor, M R Davis. Current Transplantation Reports 2015, DOI - 10.1007/s40472-015-0071-8. He personally revised the text according to the recommendations of the peer reviewers assigned by the Journal and successfully achieved publication. The manuscript was written and edited by Dr. Fries under the supervision of Dr. Michael Davis and myself.

I am Assistant Professor of Surgery at the Uniformed Services University of the Health Sciences and former Chief of Hand and Reconstructive Surgery at San Antonio Military Medical Center. In 2010, I led a combined team of military and civilian surgeons that performed the first hand transplantation for a female patient in the United States. The procedure was done at Wilford Hall Medical Center in San Antonio, Texas.

I provided subject matter expertise to Dr. Fries during his research into hand transplantation while he was stationed in San Antonio between 2012 and 2014. In particular, I offered expert advice on the use of pre-clinical models that informed his design and development of the novel model of swine forelimb transplantation. During the preliminary design phase, we wrote the above-mentioned manuscript, summarizing the 'state of the art' of pre-clinical models of hand transplantation at that time.

I consider Dr. Fries to be the primary author of this work and am very proud that he chose to include it as part of his submission for the degree of PhD by published work from your institution. Having followed his career as a surgeon scientist since 2012, highly recommend him to your program without reservation. Please feel free to contact me with any questions by either e-mail digitdoc@gmail.com or telephone 1-210-410-2140.

Sincerely,

Dmitry Tudor, M.D.



June 14, 2021

Dear Warwick University Board of Examiners,

**Dr C A Fries contribution to publications**

As Deputy Commander of the United States Army Institute of Surgical Research (USAISR), Chief of Plastic and Reconstructive Surgery, and Director of the Restorative Endeavor for Servicemembers Through Optimisation of Reconstruction (RESTOR) Program from 2012 until 2016, and Director of the US Combat Casualty Care Research Program (CCCRP) until 2020, I supervised Dr Fries research activities in the United States. This work led to the publication of the seven papers he has submitted for consideration of the award of PhD by Publication from your Institution, listed at Annex A. I am senior author on all the papers submitted.


Dr Fries worked directly to me as a full-time researcher at the USAISR from 2012 to 2014. I continued to lead his research work following his return to the UK, as part of the enduring collaboration between the USAISR, RESTOR, and the Royal Centre for Defence Medicine.

Dr Fries was integral to the conceptualisation of the experimental protocols described. He was personally responsible for the submission for regulatory approvals, logistical and project management aspects of the studies. He was the lead surgeon in the laboratory performing all surgical procedures. He liaised with the laboratory and veterinary pathology staff who performed the animal care, biochemical analyses and histopathological and statistical analyses. He personally wrote the manuscripts that were submitted and revised them following peer review. He was the corresponding author on all of these papers.

The work he started in 2012 has been continued and extended by subsequent researchers at the USAISR. In particular, the swine forelimb model he designed and the *ex vivo* perfusion techniques he developed have been the subject of several further protocols.

I unequivocally support Dr Fries application for the award of the PhD by published work from your institution and consider him to be the primary architect of the works submitted. I would be delighted to provide further information or answer any questions you may have via the contact details above.

Sincerely,



Michael R. Davis, MD, FACS, FRCS(Hon)  
Col(ret), USAF, MC  
President,  
MD<sup>3</sup> Multi-Dimensional Medical Consulting  
11826 Elmscourt  
San Antonio, TX 78230  
210-931-5555



Annex A:

**List of publications**

*Preclinical Models in Vascularized Composite Allotransplantation.* C A Fries, D W Tuder, M R Davis. Current Transplantation Reports 2015, DOI - 10.1007/s40472-015-0071-8

*A Porcine Orthotopic Forelimb Vascularized Composite Allotransplantation Model – Technical Considerations and Translational Implications.* C A Fries, C Y Villamaria, J R Spencer, R F Rickard, V S Gorantla, M R Davis. Plastic & Reconstructive Surgery 2016 Sep;138(3):461e-471e  
doi:10.1097/PRS.0000000000002451

*C1 esterase inhibitor ameliorates ischemia reperfusion injury in a swine musculocutaneous flap model.* C A Fries, C Y Villamaria, J R Spencer, T E Rassmussen, M R Davis. Microsurgery 2016 Apr 18. Doi: 10.1002/micr.30053

*Hydrogen sulphide mitigates ischemia reperfusion injury in a porcine model of vascularised composite allotransplantation.* C Villamaria, C A Fries, J R Spencer, M Roth, M Davis Ann Plas Surg 2014(May);72(5):594-598

*A Hyperbaric Warm Perfusion System Preserves Tissue Composites Ex vivo and Delays the Onset of Acute Rejection.* [Fries C A](#), [Villamaria C Y](#), [Spencer J R](#), [Lawson S](#), [Wang L](#), [Raj T](#), [Wolf E G](#), [Parida B K](#), [Gorantla V S](#), Rickard R F, [Davis M R](#). *J Reconstr Microsurg.* 2018 Aug 12. [10.1055/s-0038-1667298](#)



*Composite Graft Pre-Treatment with Hydrogen Sulfide Delays the Onset of Acute Rejection.* C A Fries, S Lawson, L Wang, M Roth, R F Rickard, V S Gorantla, M R Davis Annals of Plastic Surgery: [Jan \(9\) 2019](#) doi: 10.1097/SAP.0000000000001693

*Enzyme Activated Drug Eluting Hydrogels Delay Rejection in an Orthotopic Model of Swine Limb Vascularized Composite Allotransplantation.* **C A Fries**, S Lawson, L Wang, J Karp, R F Rickard, V S Gorantla, M R Davis. *PLOS\_ONE* <https://doi.org/10.1371/journal.pone.0210914>



Strategic Command  
Headquarters Defence Medical Services

Surgeon Captain Rory Rickard QHS PhD FRCS  
Professor of Military Surgery  
HQ Defence Medical Services  
Research and Clinical Innovation  
ICT Centre  
BIRMINGHAM  
B15 2SQ

Telephone: +44 (0)7786 365347  
MOD:   
E-mail: 

Warwick University Board of Examiners  
by email

23 Jun 2021

Dear Sir or Madam,

**Dr Charles Anton Fries. PhD by published works.**


I am the Professor of Military Surgery, a chair that has been continually appointed since 1860 and since 1960 appointed by the Royal College of Surgeons of England. In this role I drive a broad portfolio of operationally-focused research to improve the care of Servicemen and women injured on military operations. Clinically, I am a Consultant Plastic Surgeon in the Royal Navy, and Honorary Consultant Plastic Surgeon at University Hospitals Plymouth NHS Trust.

Dr Fries was a Research Fellow in my department from 2009 until his resignation from the Royal Navy in 2020. In 2012 he was awarded the Research Fellowship of the Royal College of Surgeons of England and from 2012 to 2014 he worked as a full-time researcher at the United States Army Institute of Surgical Research in San Antonio, Texas. It was at the latter institution that the research work that is the basis of the submitted publications was performed. He was my direct report during this period.

Dr Fries was integral to the conceptualisation of the experimental protocols described. He was personally responsible for the submission for regulatory approvals, logistical and project management aspects of the studies. He was the lead surgeon in the laboratory performing all surgical procedures. He liaised with the laboratory and veterinary pathology staff who performed the animal care, biochemical analyses and histopathological and statistical analyses. He was the primary architect of the works listed at the Annex, personally drafting all manuscripts and revising them following peer review. He was the corresponding author on all of these papers.

I unequivocally support Dr Fries application for the award of the PhD by published works from your institution. I would be delighted to provide further information or answer any questions you may have.

Yours,



Annex A:

**List of publications**

Enzyme Activated Drug Eluting Hydrogels Delay Rejection in an Orthotopic Model of Swine Limb Vascularized Composite Allotransplantation. C A Fries, S Lawson, L Wang, J Karp, R F Rickard, V S Gorantla, M R Davis. PLOS\_ONE <https://doi.org/10.1371/journal.pone.0210914>

A Porcine Orthotopic Forelimb Vascularized Composite Allotransplantation Model – Technical Considerations and Translational Implications. C A Fries, C Y Villamaria, J R Spencer, R F Rickard, V S Gorantla, M R Davis. Plastic & Reconstructive Surgery 2016 Sep;138(3):461e-471e  
doi:10.1097/PRS.0000000000002451

Composite Graft Pre-Treatment with Hydrogen Sulfide Delays the Onset of Acute Rejection. C A Fries, S Lawson, L Wang, M Roth, R F Rickard, V S Gorantla, M R Davis Annals of Plastic Surgery: Jan (9) 2019 doi: 10.1097/SAP.0000000000001693

A Hyperbaric Warm Perfusion System Preserves Tissue Composites Ex vivo and Delays the Onset of Acute Rejection. Fries C A, Villamaria C Y, Spencer J R, Lawson S, Wang L, Raj T, Wolf E G, Parida B K, Gorantla V S, Rickard R F, Davis M R. J Reconstr Microsurg. 2018 Aug 12. 10.1055/s-0038-1667298

June 10, 2021

To:

The Warwick University Board of Examiners

**Re: Dr. Charles Anton Fries, MD, FRCS (Plast.)**

Dear Board of Examiners:

I am writing this letter attesting to Surg Lt Cdr C. Anton Fries's contributions to the research that supported his PhD program.

I am currently Professor of Surgery (with tenure) in the Department of Surgery at the Wake Forest University Medical Sciences and Director of the Reconstructive Transplant Program. My academic and research interests include clinical hand and face transplantation and novel immunomodulatory protocols directed at reducing long-term risk due to immunosuppressive drugs. In January 1999, I was in a team of 18 surgeons to perform the nation's first hand transplant which is the longest surviving and most successful hand transplant done to date in the world at 22 years after surgery. Between 2006 and 2017, I was team surgeon on 8 other hand transplants performed the University of Pittsburgh Medical Center. I am trained in general and hand surgery with over 2 decades of research and clinical experience in reconstructive transplantation. I have authored more than 100 scientific papers including 20 book chapters. I currently serve as the President the International Society of Vascularized Composite Allotransplantation. Over the past decade, I also served as Chief Scientist for the 59th Medical Wing, US Air Force, and Reconstructive Endeavour for Servicemembers Through Optimization of Reconstruction (RESTOR) Program, in San Antonio, Texas.

During his SpR training, Dr. Fries spent three years (2012-2015) in the USA as Research Fellow in the US Army Institute of Surgical Research (USAISR) in San Antonio, Texas under the mentorship of Lt. Col. Michael Davis, Chief of Plastic and Reconstructive Surgery at San Antonio Military Medical Center. Although I have not directly supervised Anton, I have had the opportunity to co-mentor him with Dr. Davis on research projects involving large animal VCA at USAISR, which is the largest military research facility in the USA. Both Dr. Davis and I have worked closely with Anton since early 2012 on multiple projects that contributed to his PhD.


My expertise in pre-clinical models was instrumental to the design and development of Dr Fries orthotopic forelimb model of swine forelimb transplantation. To his credit, Anton successfully implemented novel immunomodulatory and local immunosuppressive therapy protocols (nanoparticles and hydrogel-based platforms) in this stringent immunologic model with the full complement of VCA component tissues.

Beyond validating these novel immunotherapies in a large animal translational porcine forelimb VCA model, Dr. Fries also took the initiative to address the technical, procedural, preservation, immunologic and neuroregenerative hurdles in VCA.

Dr Fries was integral to the conceptualisation of the experimental protocols on all the projects and personally responsible for the submission for regulatory approvals, logistical and project management aspects of the studies. He was the lead surgeon in the RESTOR laboratory performing all surgical procedures. He liaised with the laboratory and veterinary pathology staff who performed the animal care, biochemical analyses and histopathological and statistical analyses. He personally wrote the manuscripts that were submitted and revised them following peer review. He was the corresponding author on all of these papers. As his co-mentor, I was a co-senior author on the four papers listed at Annex A.

I unequivocally support Dr Fries application for the award of the PhD by published work from your institution and consider him to be the primarily responsible for the works submitted. I would be delighted to provide further information or answer any questions you may have via the contact details below.

Sincerely,



**Vijay S. Gorantla, MD, PhD, MMM, FRCS**

Professor (with tenure)  
Surgery | Ophthalmology | Bioengineering  
Wake Forest School of Medicine  
Director | Vascularized Composite Allotransplantation Program  
Expert Consultant for Military Medicine | Wake Forest Institute for Regenerative Medicine  
Suite 333 | Richard H. Dean Biomedical Building  
391 Technology Way  
Winston- Salem | NC 27101  
Office: 336-713-1494 | Cell: 724-624-5915 | Email: [vgorantl@wakehealth.edu](mailto:vgorantl@wakehealth.edu)

## **Annex A:** List of publications

1. A Porcine Orthotopic Forelimb Vascularized Composite Allotransplantation Model – Technical Considerations and Translational Implications. C A Fries, C Y Villamaria, J R Spencer, R F Rickard, V S Gorantla, M R Davis. *Plastic & Reconstructive Surgery* 2016 Sep;138(3):461e-471e doi:10.1097/PRS.0000000000002451
2. A Hyperbaric Warm Perfusion System Preserves Tissue Composites Ex vivo and Delays the Onset of Acute Rejection. Fries C A, Villamaria C Y, Spencer J R, Lawson S, Wang L, Raj T, Wolf E G, Parida B K, Gorantla V S, Rickard R F, Davis M R. *J Reconstr Microsurg*. 2018 Aug 12. 10.1055/s-0038-1667298
3. Composite Graft Pre-Treatment with Hydrogen Sulfide Delays the Onset of Acute Rejection. C A Fries, S Lawson, L Wang, M Roth, R F Rickard, V S Gorantla, M R Davis *Annals of Plastic Surgery*: Jan (9) 2019 doi: 10.1097/SAP.0000000000001693
4. Enzyme Activated Drug Eluting Hydrogels Delay Rejection in an Orthotopic Model of Swine Limb Vascularized Composite Allotransplantation. C A Fries, S Lawson, L Wang, J Karp, R F Rickard, V S Gorantla, M R Davis. *PLOS\_ONE* <https://doi.org/10.1371/journal.pone.0210914>

## Appendix 10 – Publications

Citations - 638

H-Index - 15

*Abdominal Wall Transplantation: Indications and Outcomes* C Honeyman, R Dolan, H Stark, C A Fries, S Reddy, P Allan, G Vrakis, A Vaidya, G Dijkstra, S Hofker, T Templeman, P Werker, D Erdmann, K Ravindra, D Sudan, P Friend, H Giele. *Curr Transpl Rep* 2020 doi.org/10.1007/s40472-020-00308-9

*Vascularised composite allotransplantation in solid organ transplant recipients: a systematic review* C Honeyman, H Stark, **C A Fries**, V S Gorantla, M R Davis, H P Giele *Journal of Plastic Reconstructive & Aesthetic Surgery* 2020 Aug 10.1016/j.bjps.2020.08.052

*Trends in decubitus ulcer disease burden in European Union 15+ countries 1990-2017.* R Goodall, **C A Fries**, PRSGO 2020 - IN PRESS

*Patient safety associated with the surgical treatment of bone and soft tissue tumours during the COVID-19 pandemic - Results from an observational study at the Oxford Sarcoma Service.* R B Rajasekaran, S Kotecha, D Whitwell, T D A Cosker, P Critchley, **C A Fries**, D Pigott, C L M H Gibbons, A Carr. *International Orthopaedics* July 2020 doi: 10.1007/s00264-020-04736-1

*Military VCA in the World.* **C A Fries**, D Tuder, V S Gorantla, R K Chan, M R Davis, *Cur Transplantation Reports* 2020 ()1-5 doi: 10.1007/s40472-020-00294-y

*Change in the face of the COVID-19 pandemic: shaping plastic surgery services of the future* A Shaw, R Goodall, A Armstrong, **C A Fries**, *Plastic and Reconstructive Surgery* May 2020 doi: 10.1097/PRS.00000000000007219

*Translational techniques from cleft to cosmetic rhinoplasty* H S Stark, **C A Fries**, N S Mercer. *Archives of Plastic Surgery* 2019 doi: 10.5999/aps.2018.00185

*Complete laparoscopic removal of retropubic midurethral tape (tension-free vaginal tape) from the obdurator nerve: a multidisciplinary approach* W R Cooke R Cartwright, **C A Fries**, N Price *International Urogynecology Journal* Jun 2019 DOI: doi.org/10.1007/s00192-019-04016-6

*Dorsal Wrist Placement for Vascularized Submental Lymph Node Transfer Significantly Improves Breast Cancer-Related Lymphedema.* H A Aljaaly, **C A Fries**, M H Cheng. Plastic and Reconstructive Surgery – Global Open. 7(2):e2149, February 2019.

*Vascularised Composite Allotransplantation – Basic Science and Clinical Applications.* Honeyman C, **Fries CA**. International Journal of Orthoplastic Surgery. 2019;2(1):13–22. DOI: <http://doi.org/10.29337/ijops.28>

*Techniques and Outcomes in Microsurgical Soft Palate Reconstruction.* **C A Fries**, N Al Deek, F C Wei. Head & Neck. 2019;1–8. DOI: 10.1002/hed.25662

*Enzyme Activated Drug Eluting Hydrogels Delay Rejection in an Orthotopic Model of Swine Limb Vascularized Composite Allotransplantation.* **C A Fries**, S Lawson, L Wang, J Karp, R F Rickard, V S Gorantla, M R Davis. PLOS\_ONE <https://doi.org/10.1371/journal.pone.0210914>

*Composite Graft Pre-Treatment with Hydrogen Sulfide Delays the Onset of Acute Rejection.* **C A Fries**, S Lawson, L Wang, M Roth, R F Rickard, V S Gorantla, M R Davis Annals of Plastic Surgery: Jan (9) 2019 doi: 10.1097/SAP.0000000000001693

*Patient Reported Outcomes for Toe-to-Hand Transfer – A Prospective Longitudinal Study.* T Y Tsai, **C A Fries**, J C Shiao, C C Hsu, Y T Lin, F C Wei, C H Lin. Plast Reconstr Surg. 2019 Jan 21. doi: 10.1097/PRS.00000000000005422.

*A Hyperbaric Warm Perfusion System Preserves Tissue Composites Ex vivo and Delays the Onset of Acute Rejection.* **Fries C A**, Villamaria C Y, Spencer J R, Lawson S, Wang L, Raj T, Wolf E G, Parida B K, Gorantla V S, Rickard R F, Davis M R. J Reconstr Microsurg. 2018 Aug 12. 10.1055/s-0038-1667298

*Upper Limb Reconstructive Transplantation in Military Recipients: Summary of World Experience* **C A Fries**, H L Stark, D Tuder, S Iyer, V S Gorantla, M R Davis, R F Rickard. Journal of the Royal Naval Medical Service 2018;104(1):6-11

*Plastic Surgery Pioneers of the Central Powers in the Great War* R L Thomas, **C A Fries**, D Hodgkinson Craniofacial Trauma and Reconstruction – 2018 DOI: 10.1055/s-0038-1660443

*The Modified Furlow Palatoplasty* H S Stark, **C A Fries**, N S Mercer. Medical Research Archives 2017 Nov;5(11):

*Soft Tissue Reconstruction..* **C A Fries**, M R Davis, R F Rickard Ballistic Trauma 4<sup>th</sup> edition, Springer international.

*Ballistic Wound Management and Infection Prevention.* J G Penn-Barwell, **C A Fries**, R F Rickard Ballistic Trauma 4<sup>th</sup> edition, Springer International.

*Crossfitter's knee: patellofemoral chondral injury following high-intensity functional training.* J Jackson, S Hart, **C A Fries**, J Robinson, J Murray, A M Wood. Journal of the Royal Naval Medical Service 2017



*Dismounted complex blast injuries: a comprehensive review of the modern combat experience.* J W Cannon, L J Hofmann, S C Glasgow, B K Potter, C J Rodriguez, L C Cancio, T E Rasmussen, **C A Fries**, M R Davis, J R Jezior, R J Mullins, E A Elster. *J Am Coll Surg.* 2016 Oct;223(4):652-664.e8.

*Development of a Clinical Vascularized Composite Allotransplantation Program: Requirements and Recommendations.* S Lawson, L Wang, **C A Fries**, M R Davis, V S Gorantla, Book Chapter in "From Auto-to-Allo Transplantation", Editor – F C Wei. Publisher – Karger. DOI:10.1159/000444967

*A Porcine Orthotopic Forelimb Vascularized Composite Allotransplantation Model – Technical Considerations and Translational Implications.* **C A Fries**, C Y Villamaria, J R Spencer, R F Rickard, V S Gorantla, M R Davis. *Plastic & Reconstructive Surgery* 2016 Sep;138(3):461e-471e doi:10.1097/PRS.0000000000002451

*C1 esterase inhibitor ameliorates ischemia reperfusion injury in a swine musculocutaneous flap model.* **C A Fries**, C Y Villamaria, J R Spencer, T E Rasmussen, M R Davis. *Microsurgery* 2016 Apr 18. Doi: 10.1002/micr.30053

*Factors influencing infection in 10 years of battlefield open tibia fractures.* J G Penn-Barwell, P M Bennett, D E Mortiboy, **C A Fries**, A F G Groom, I D Sargeant. *Strat Traum Limb Recon* DOI 10.1007/s11751-016-0250-x

*Gun-shot injuries in UK military casualties – Features associated with wound severity.* Penn-Barwell J G, Sargent I D, Severe Lower Extremity Combat Trauma (SeLECT) Study Group – J G Penn-Barwell, P M Bennett, **C A Fries**, J M Kendrew, M Midwinter, J Bishop, R F Rickard, I D Sargeant, K Porter, T Rowlands, A Mountain, A Kay, D Mortiboy, T Stevenson, R W Myatt

*Medium-term outcomes following limb salvage for severe open tibia fracture are similar to trans-tibial amputation.* Penn-Barwell JG, Myatt RW, Bennett PM, Sargeant ID, Severe Lower Extremity Combat Trauma (SeLECT) Study Group. *Injury.* Elsevier; 2015 Feb;46(2):288–91.

*High velocity gunshot injuries to the extremities: management on and off the battlefield.* Penn-Barwell, J. G., Brown, K. V., **Fries, C. A.** (2015). *Current Reviews in Musculoskeletal Medicine.* <http://doi.org/10.1007/s12178-015-9289-4>

*Preclinical Models in Vascularized Composite Allotransplantation.* **C A Fries**, D W Tuder, M R Davis. *Current Transplantation Reports* 2015, DOI - 10.1007/s40472-015-0071-8

*Reconstructive Plastic Surgery.* **C A Fries**, D Evriviades, M R Davis. Book Chapter in *War Trauma: Principles and Practice of Management.* Editor – J Garner, in press

*Hydrogen sulphide mitigates ischemia reperfusion injury in a porcine model of vascularised composite allotransplantation.* C Villamaria, **C A Fries**, J R Spencer, M Roth, M Davis *Ann Plas Surg* 2014(May);72(5):594-598

*Prospective randomised controlled trial of nanocrystalline silver dressing versus plain gauze as the initial post-debridement management of military wounds on wound microbiology and healing* **C A Fries**, J G Penn-Barwell, Y Ayalew, S L A Jeffery, K Porter, M J Midwinter, *Injury*. 2014 Jul;45(7):1111-6. doi: 10.1016/j.injury.2013.12.005

*Outcomes following battlefield trauma in Royal Naval Personnel* J G Penn-Barwell **C A Fries**, M Midwinter, Baker. *Mil Med J* 2013(Nov);178(11):1222-1226

*Battlefield scrotal trauma: How should it be managed in deployed military hospitals?* R J Williams, **C A Fries**, M Midwinter, A W Lambert. *Injury* 2013(Sep);44(9):1246-1249

*Severe open tibia fractures in combat trauma: management and preliminary outcomes.* J G Penn-Barwell, P M Bennet, **C A Fries**, J M Kendrew, M J Midwinter, R F Rickard. *Bone Joint J*. 2013;95-B(1):101-5

*Aggressive soft tissue infections and amputation in military trauma patients.* J G Penn-Barwell, **C A Fries**, I D Sargeant, P M Bennett, K Porter. *JRNMS* 98(2):14-8

*Surgical Training in Camp Bastion, Afghanistan,* **C A Fries**, R F Rickard, *JRNMS*. 98(2):23-6

*Combat lower limb amputation: the contemporary British Military experience.* J G Penn-Barwell, **C A Fries**, I D Sargeant, K Porter. *Journal of Bone and Joint Surgery, British Volume* 94 (SUPP XV), 11-11

*Military trauma care in Birmingham: observational study of care requirements and resource utilisation.* P C Jackson, M Foster, **C A Fries**, S L A Jeffery *Injury*. 2014 Jan;45(1):44-9. doi: 10.1016/j.injury.2012.08.036. Epub 2012 Sep 19.

*Use of topical negative pressure in British servicemen with combat wounds.* J Penn-Barwell, **C A Fries**, L Street, S L A Jeffery, *ePlasty* 2011;11:e35. epub2011Aug19

*Management of intestinal injuries in deployed UK hospitals.* **C A Fries**, N R M Tai, T J Hogetts, M J Midwinter, D M Bowley, *JRAMC* 2011 Dec;157(4):370-374

*Topical Negative Pressure and Military Wounds – A Review of the Evidence.* **C A Fries**, S L A Jeffery, A R Kay. *Injury, Int. J. Care Injured* 41 (2010) 708-712

*Damage Control Surgery in the Era of Damage Control Resuscitation.* **C A Fries**, M Midwinter, *Surgery Journal* 28(11); 563-567.

*The Team Works – a Multidisciplinary Approach.* **C A Fries**, M Midwinter, S E P Bree, P J Taylor, M K Peterson. *J R Nav Med Ser*. 2007;93(3) 125-128

*A Thorn in the Side.* **C A Fries**, J K Campbell. *J R Nav Ser*. 2006;92(3) 121-3

*Hitting the Nail on the Head* **C A Fries**, I Higginson. Emerg Med J 2007 Jan;24(1):e3

*A Comparison Between the Short Term and Long Term Benefits of Screening for Abdominal Aortic Aneurysms.* A B M Wilmink, M W C Claridge, **C A Fries**, O Will, D J Adam, C R G Quick, A W Bradbury. Eur J Vasc Endovasc Surg, 2006 Jul;32(1):16-20

## Appendix 11

### Post – viva thesis addendum – future development of submitted papers

#### 1. Preclinical Models in Vascularized Composite Allotransplantation

Since the publication of my review, a 2019 review of animal models for facial transplantation identified three new small animal (rat) models and no new large animal models of facial transplantation (Rodriguez et al). Similarly, regarding limb transplantation there have been relatively few novel animal models described in the last seven years. Interestingly this includes three variations of swine forelimb models *vide infra*. I believe this reflects the maturity of the field, as Rodriguez et al comment; the focus of Vascularized Composite Allotransplantation (VCA) research has shifted from technical surgical challenges to immunological challenges.

I have an active grant submission in collaboration with the United States Army Institute of which will utilize the gracilis model again to evaluate a novel immunomodulatory therapeutic.

#### 2. A Porcine Orthotopic Forelimb Vascularized Composite Allotransplantation Model – Technical Considerations and Translational Implications

Since my description of this model, further groups have utilized swine forelimb transplantation to evaluate ischemia reperfusion injury (IRI), *ex vivo* perfusion of vascularized composite allotransplants, and rejection phenomena. They identify that the composite nature of the graft makes it superior to models that contain fewer tissue types. Interestingly, and corresponding with our own findings regarding animal husbandry, they have used alternative methods to recover the animals. One group maintained subjects anaesthetized for a 12-hour post-transplant phase to enable repeated measures of IRI and immunologic rejection phenomena. Another performed reperfusion *in vitro*, conducting biochemical analysis after reperfusion the limb with whole blood, but not replanting the limb. Finally, an abstract has been published of a functional recovery model at the trans-humeral (higher) level, however the full paper remains in press.

#### 3. C1 esterase inhibitor ameliorates ischemia reperfusion injury in a swine musculocutaneous flap model &

#### 4. Hydrogen sulphide mitigates ischemia reperfusion injury in a porcine model of vascularised composite allotransplantation

As reiterated by my results, the first 12 (and 24) hours post auto or allo-transplantation are where the inflammatory milieu associated with IRI is at its most significant. Post-op timepoints of blood draws in my experiments were dictated by animal welfare and logistical constraints to reduce repeated episodes of anaesthesia. In future such experiments it would be highly instructive to maintain the first anaesthetic for a longer period (up to 12 hours) following transplantation, to enable hourly blood draws and / or biopsies thus increasing the granularity of the data collected. This would provide a clear baseline as to the effect of

IRI and acute immunologic rejection (AR) phenomena, provided such an extended anaesthetic period could be safely delivered.

In addition, it is acknowledged that the IRI observed has minimal clinically measurable effects on flap survival. However, it does influence the later development of AR and, by extension, chronic rejection. Establishing this baseline in more detail would enable us to tease out more information on the relationship between initial IRI and later rejection phenomena as they manifest.

## **5. A Hyperbaric Warm Perfusion System Preserves Tissue Composites *Ex Vivo* and Delays the Onset of Acute Rejection**

Since the publication of my paper the solid organ transplant (SOT) community has vigorously pursued *ex vivo* graft perfusion systems, also using oxygenated non-cellular perfusates, including University of Wisconsin Solution. There is now a body of evidence supporting the efficacy of machine perfusion, without the use of hyperbaric oxygen, as well as the use of hypothermia (4°C) and sub-normothermic (21°C) perfusion. The former temperature reduces metabolic tissue demands however there is increased oedema formation in the graft. The latter has benefits of reducing oedema and is logistically very favourable.

It would therefore be very interesting to repeat my experiments with additional controls, using the same perfusion system but without the hyperbaric chamber. As well as at different temperatures, to tease out more mechanistic information regarding the beneficial effects observed.

## **6. Composite Graft Pre-Treatment with Hydrogen Sulphide Delays the Onset of Acute Rejection**

Regarding this paper, as well as the allo-transplant phase of paper 5, it is recognized that the biochemical and histological analysis of the rejection phenomena were constrained by the availability of tests at the various facilities, the expertise of the pathology staff available, and the technology of the time. It may be possible to re-test or re-review some of our specimens to achieve further granularity of results. The immunohistochemistry specimens could be quantitatively analysed to deliver more information. Since my work was performed, the VCA lab in Oxford where I subsequently worked, has started to use new techniques to evaluate rejection phenomena. These include rates of gene expression in transplanted tissues (nano-string technology) as well as more detailed analysis of T-Cell expression by mixed leukocyte reaction. It may be possible to perform a post hoc analysis of my specimens.

## **7. Graft-implanted, enzyme responsive, tacrolimus-eluting hydrogel enables long-term survival of orthotopic porcine limb vascularized composite allografts: A proof of concept study**

The use of topical immunosuppression remains a hot topic in VCA research for the reasons described in my thesis. There have been further developments in smart delivery systems (eg nano-spheres, nano-particles and tyrospheres), as well as interest in developing topical formulations of drugs. The most common topically delivered agent continues to be tacrolimus, due to its efficacy and suitability as a topical agent, however last year Gorantla et al published their early work in describing the pharmacokinetics of their novel formulation of mycophenolate mofetil. A 2020 review article by Pomohac et al identified 10 preclinical studies of targeted immunosuppression (including my own), of which seven used tacrolimus and the remaining three rapamycin, efomycin and correolide C, respectively.

This was the most impactful paper of my submission. However, it could have been strengthened by the use additional controls to further un-pick the targeted-versus-systemic effects of the drug delivery system. Whilst the tissue and blood samples were compelling, regarding the temporal drug level spikes, witnessed at the time of initial transplantation and later rejection, injecting the hydrogel into the contralateral, non-transplanted limb would have provided powerful evidence to support or discard this hypothesis.

The effect of tacrolimus on nerve regeneration, and its role in functional outcome in both extremity and maxillofacial VCA, is very exciting and has not been fully quantified. The results of nerve conduction studies performed on my own subjects have never been published. In addition, the study I performed in Taipei using a rat facial nerve injury model, to evaluate the effect of the same tacrolimus hydrogel on functional nerve recovery, did not yield positive results, due to uniformly excellent nerve recovery in the rats. Revision of the model may yet yield this information in future.

C A Fries